

# Elevation of the First Metatarsal Following the Modified Lapidus: a Radiographic Comparison of Two Techniques

Nathan S. Shane DPM<sup>1</sup>, Zachary L. Rasor DPM<sup>2</sup>, Casie M. Blanton DPM<sup>3</sup>, Jordan A. Henning DPM<sup>4</sup>, Jared M. Maker DPM<sup>5</sup>

University of Cincinnati Medical Center

1: Resident Physician, University of Cincinnati Medical Center; 2: Resident Physician, University of Cincinnati Medical Center; 3: Resident Physician, University of Cincinnati Medical Center; 4: Resident Physician, University of Cincinnati Medical Center; 5: Attending Physician, University of Cincinnati Medical Center

## Statement of Purpose

Continued developments in the surgical technique for the modified Lapidus arthrodesis are being made with the goal of creating a more desirable and reproducible outcome. Specifically, the authors feel that the joint preparation technique of curettage, which the senior author now routinely utilizes, offers many advantages when compared to the more traditional technique of planal saw resection. Among these advantages, the authors have noticed more reproducible deformity correction with a decreased incidence of post-operative metatarsus primus elevatus. The aim of the current study is to compare radiographic outcomes of these two surgical techniques with respect to iatrogenic metatarsus primus elevatus.

## Methodology

Seventeen (17) consecutive patients receiving a modified Lapidus bunionectomy at the same institution were included in this study. These patients were then divided into two groups, those where anatomic curettage joint preparation was used (8 patients) (Group 1), and those where planal resection joint preparation was used (9 patients) (Group 2). Radiographs from each group were then compared with respect to first metatarsal alignment and in the sagittal plane post-operatively.

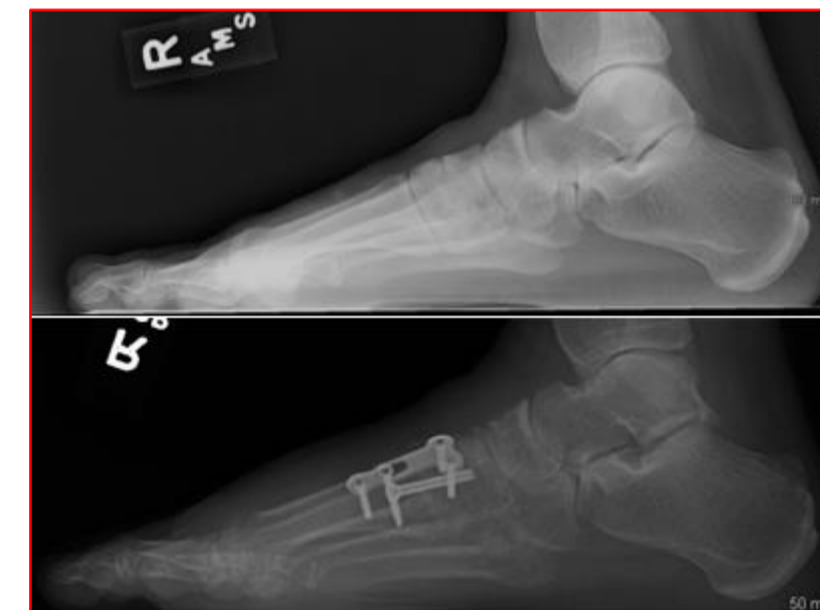The degree of first metatarsal elevation was measured and compared to its preoperative value according to the Seiberg index. The average value as well as the overall incidence between each group was then compared.

## Procedure

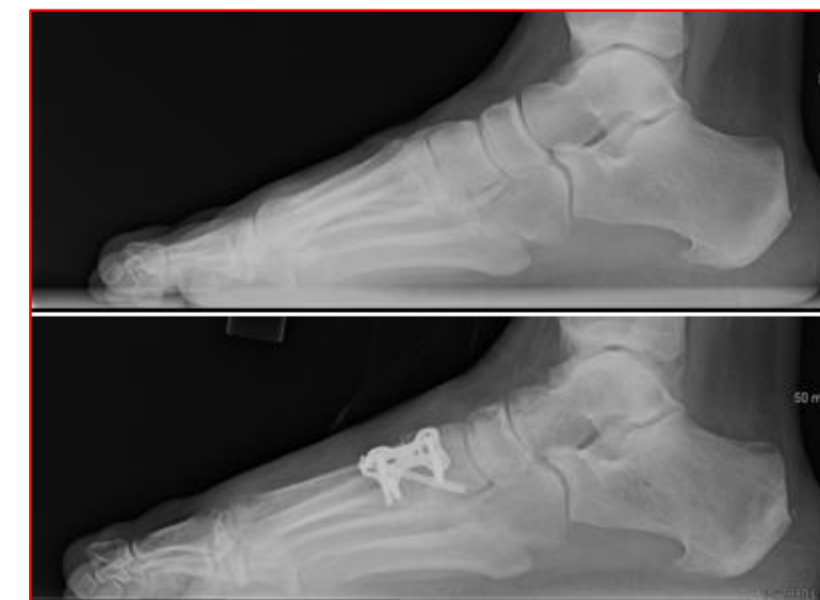In both groups, a dorsomedial incisional approach was utilized. Standard layered and subperiosteal dissection was performed to allow access to the first tarsometatarsal joint. Once the joint was exposed, joint preparation was carried out via planal resection with an oscillating saw (group 1) and via curettage (group 2). A similar fixation construct consisting of an interfragmentary compression screw and locking plate was utilized in all but two (2) patients (one in each group).

## Results

Both the overall incidence and average degree of post-operative first metatarsal elevation was significantly lower in the curettage joint preparation group (Group 1) when compared to the planal resection study group (Group 2) at final follow-up. The overall incidence of post-operative elevation was 77.8% (7 of 9) in Group 1 versus 12.5% (1 of 8) in Group 2. Average degree of post-operative elevation was 5.4 degrees in Group 1 versus 0.87 degrees in Group 2.



Group 1 (above): weight bearing lateral radiograph preoperatively and at 12 months post-operatively revealing maintenance of preoperative first ray sagittal plane alignment



Group 2 (above): weight bearing lateral radiograph preoperatively and at 12 months post-operatively revealing significant iatrogenic first metatarsal elevation (6.99 degrees in figure shown)

## Analysis & Discussion

Several radiographic outcome parameters have been studied for the modified Lapidus arthrodesis. The authors are unaware of any studies comparing the technique of curettage joint preparation to the traditional traditional planal resection technique with respect to post-operative first ray alignment, alignment, specifically in the sagittal plane. The current study describes an increasingly popular technique for the modified Lapidus arthrodesis with reproducible deformity correction and low incidence and degree of post-operative metatarsus primus elevatus, a commonly encountered problem with the more traditional planar resection approach.

Figure 1

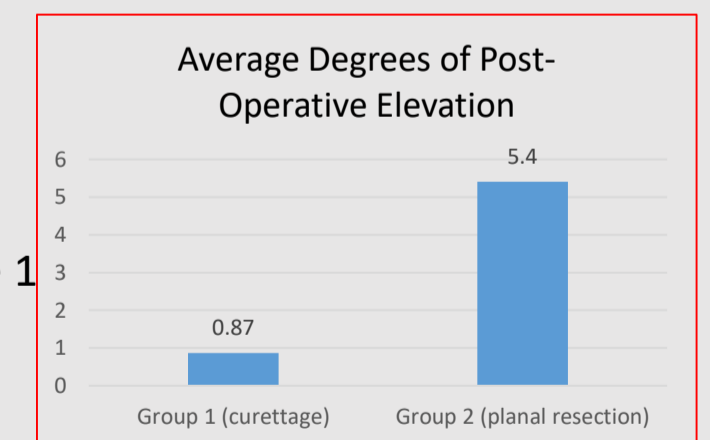


Figure 2

