


# A Novel Treatment For Limb Salvage Following 1<sup>st</sup> Metatarsal Phalangeal Joint Arthrodesis Infection with the Use of a Silver Impregnated Antimicrobial Dermal Graft: A Case Report

Rhonda Cornell, DPM, FACFAS <sup>AB</sup> ;Tarek Sayed, DPM <sup>C</sup> ; Sarah Shipley, DPM <sup>C</sup> ; Jocelyn Guillen, DPM <sup>C</sup>



<sup>A</sup> Attending, Crozer-Keystone Health System Podiatric Surgical Residency, Upland, PA

<sup>B</sup> Wound Care Physician, DCMH, Center for Wound Healing. Drexel Hill, PA

<sup>C</sup> Podiatric Surgical Resident, Crozer-Keystone Health System Podiatric Surgical Residency, Upland, PA



## Statement of Purpose

This case presents a novel treatment of avoiding an amputation, by utilizing a Silver impregnated Antimicrobial Dermal Graft as a biologic spacer in the 1<sup>st</sup> metatarsal phalangeal joint, following hardware removal and resection of infected tissue and bone.

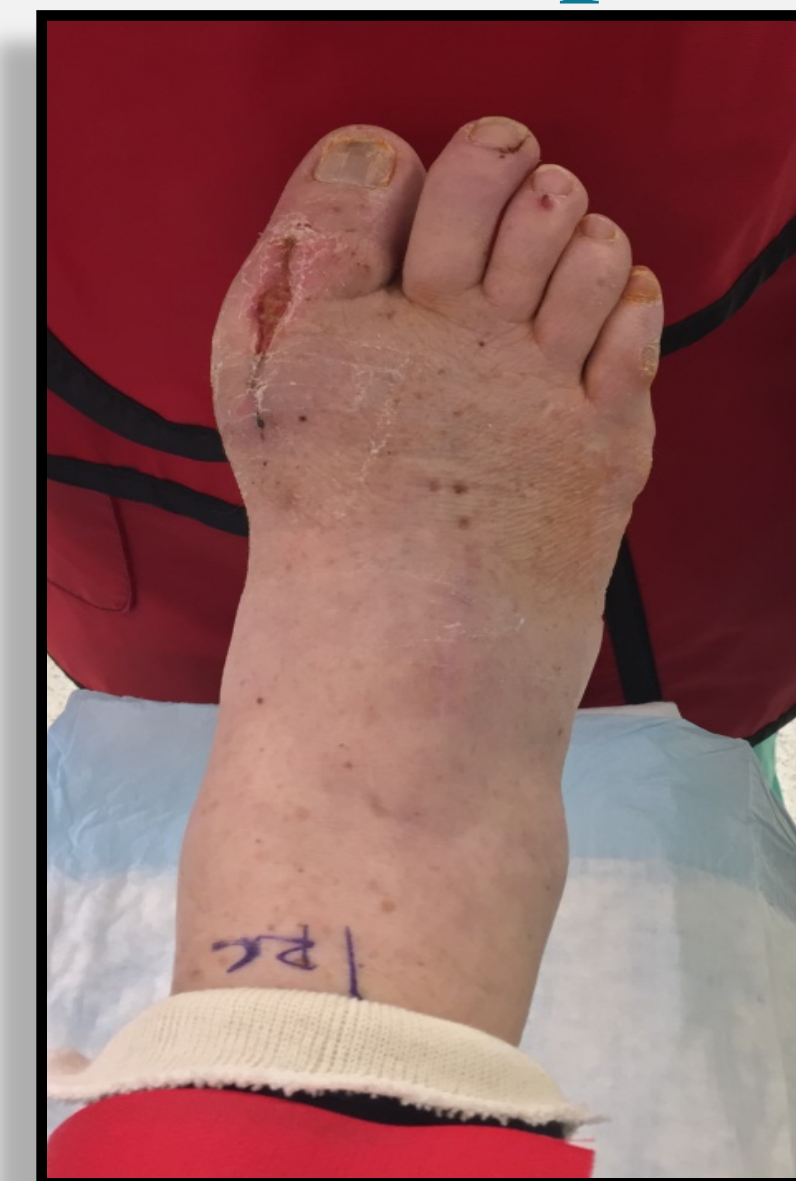## Literature Review

Revision surgeries for 1<sup>st</sup> metatarsal phalangeal joint (MPJ) deformities are often complex and challenging. Arthrodesis of the 1<sup>st</sup> MPJ has been known to provide union rates greater than 90%. However, questions remain regarding treatment options when it fails. There is very limited published data regarding treatment options for failed MPJ arthrodesis; even more limited when it fails secondary to infection. When there is infection, placement of hardware in a septic joint or within osteomyelitis is not recommended. The use of an antibiotic spacer has been described, however they can offer less joint function. And the risk of an amputation is high with this complication in a patient with diabetes and neuropathy.

## Case Report

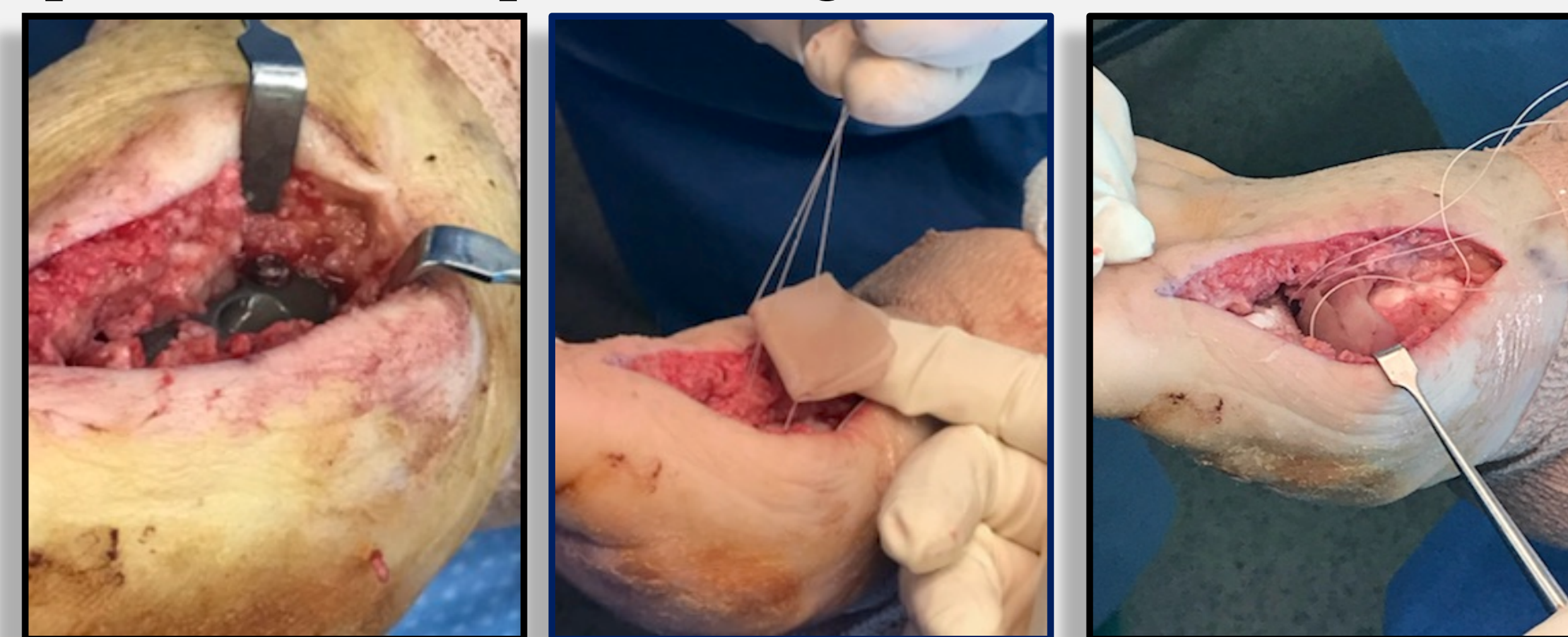
A 51 year-old neuropathic, diabetic female presented for a 2<sup>nd</sup> opinion after undergoing a 1<sup>st</sup> MPJ arthrodesis for a chronic right plantar hallux ulcer. However this had failed due to infection. At the 1 week post-operative visit clinical exam revealed a surgical wound infection with dehiscence of the incision and radiographs revealed hardware failure with screws backing out. Due to the patient's comorbidities and risk of amputation, Infectious disease was consulted for long term antibiotic management.

## Case Report



*Pre-operative clinical presentation*

In an attempt to salvage the 1<sup>st</sup> ray, all hardware was removed and a revisional 1<sup>st</sup> MPJ arthroplasty was performed. A Silver Impregnated Antimicrobial Dermal Graft was utilized as a spacer. Application of this antimicrobial graft was performed in a purse string fashion.

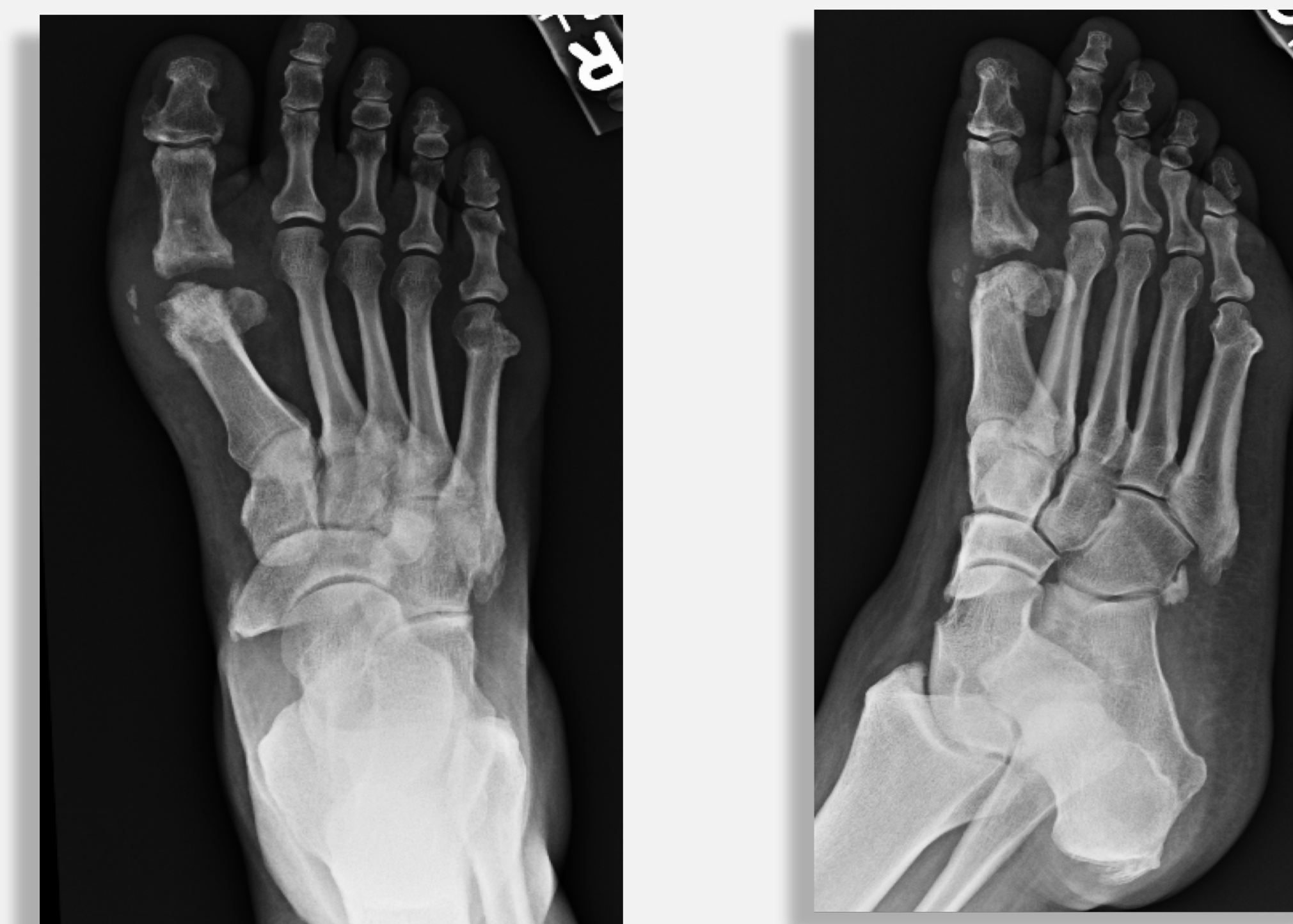

*Intra-operative clinical presentation*

## Results

Range of motion of the joint was restored after the arthroplasty of the 1<sup>st</sup> MPJ with the application of the silver impregnated antimicrobial graft, off loading the plantar area of pressure. The surgical site healed post-operatively with no signs of infection. The patient has since transitioned into normal diabetic shoe gear, and has been completely wound-free and infection free for over a year. Radiographs demonstrate a stable, reshaped metatarsal and a maintained joint space.

## Results



*Immediate Post-operative X-rays*

## Discussion

Prophylactic surgery in a neuropathic, diabetic patient to heal or help prevent a wound can be risky, as complication rates are increased due to multiple factors. Such factors include neuropathy, ambulatory status, patient compliance, bone stock, nutritional status, and diabetic control. Wound dehiscence, infection and hardware failure are a few possible post-operative complications and together are a difficult combination to treat. If left untreated, hardware failure may lead to non-union and ultimately limb threatening infection, leading to amputation. In the case of infections after an arthrodesis with hardware failure, the hardware should be removed and the underlying infection addressed. If the hardware is replaced there becomes a concern that it could again become a nidus for further infection. Arthroplasty of the 1<sup>st</sup> MPJ can be a viable option for limb salvage of a failed arthrodesis in this high risk population.

## Discussion

With 1<sup>st</sup> MPJ arthroplasty procedures, surgeons look for different ways to attempt to recreate the joint space. In this case, a Silver impregnated Antimicrobial Dermal Graft was purse stringed into place in the 1<sup>st</sup> MPJ. This graft offers a unique antimicrobial dermal repair scaffold containing Ionic Silver, which aids in fighting infection and providing a biologic to maintain metatarsal length and joint space. The dermal graft that was utilized for this study is routinely used in topical applications of challenging wounds to promote healing. Derived from fetal bovine dermis, it is particularly rich in Type III collagen, a collagen that is active in developing and healing tissues. The collagen allows for a stronger integrity and pliability of the graft.. This graft was an excellent surgical option for this patient to restore infection free and pain-free range of motion, and to prevent the need for an amputation.

## References

1. First metatarsophalangeal arthrodesis for severe bone loss. Schuh R, Trnka H. Foot Ankle Clin. 2011;16:13–20.
2. Metanalysis of first metatarsophalangeal joint implant arthroplasty. Cook E, Cook J, Rosenblum B. J Foot Ankle Surg. 2009;48:180–190.
3. Bitterman A, Mathew C, Patel M, Gurtowski JP. Antibiotic Spacer Arthroplasty for Revision MTP Arthrodesis: A Novel Means to Build the Implant: A Case Report. *Cureus*. 2016;8(3):e537. Published 2016 Mar 21.
4. Sullivan MR. Hallux rigidus: MTP implant arthroplasty. Foot Ankle Clin. 2009 Mar;14(1):33-42. doi: 10.1016/j.fcl.2008.11.009. Review. PubMed PMID: 19232990.

**Financial Disclosures:** The authors were not financially sponsored by any third party for the production of this poster.