

Achilles Tendon Rupture in the Setting of Alkaptonuric Ochronosis

Institute for Orthopaedics
and Neurosciences

CARILION CLINIC

Wesley M. Leong, DPM¹, Wendy J. Introne, MD², John R. Clements, DPM^{3,4}

¹Resident Physician , PGY3 Carilion Roanoke Memorial Hospital, Roanoke, VA, ²Clinical Geneticist, National Human Genome Research Institute,
³Foot and Ankle Co-Section Chief, Carilion Roanoke Memorial Hospital, Roanoke,VA, ⁴Assistant Professor, Virginia Tech Carilion School of Medicine, Roanoke,VA

VTC
Virginia Tech Carilion
School of Medicine and
Research Institute

Purpose and Literature Review

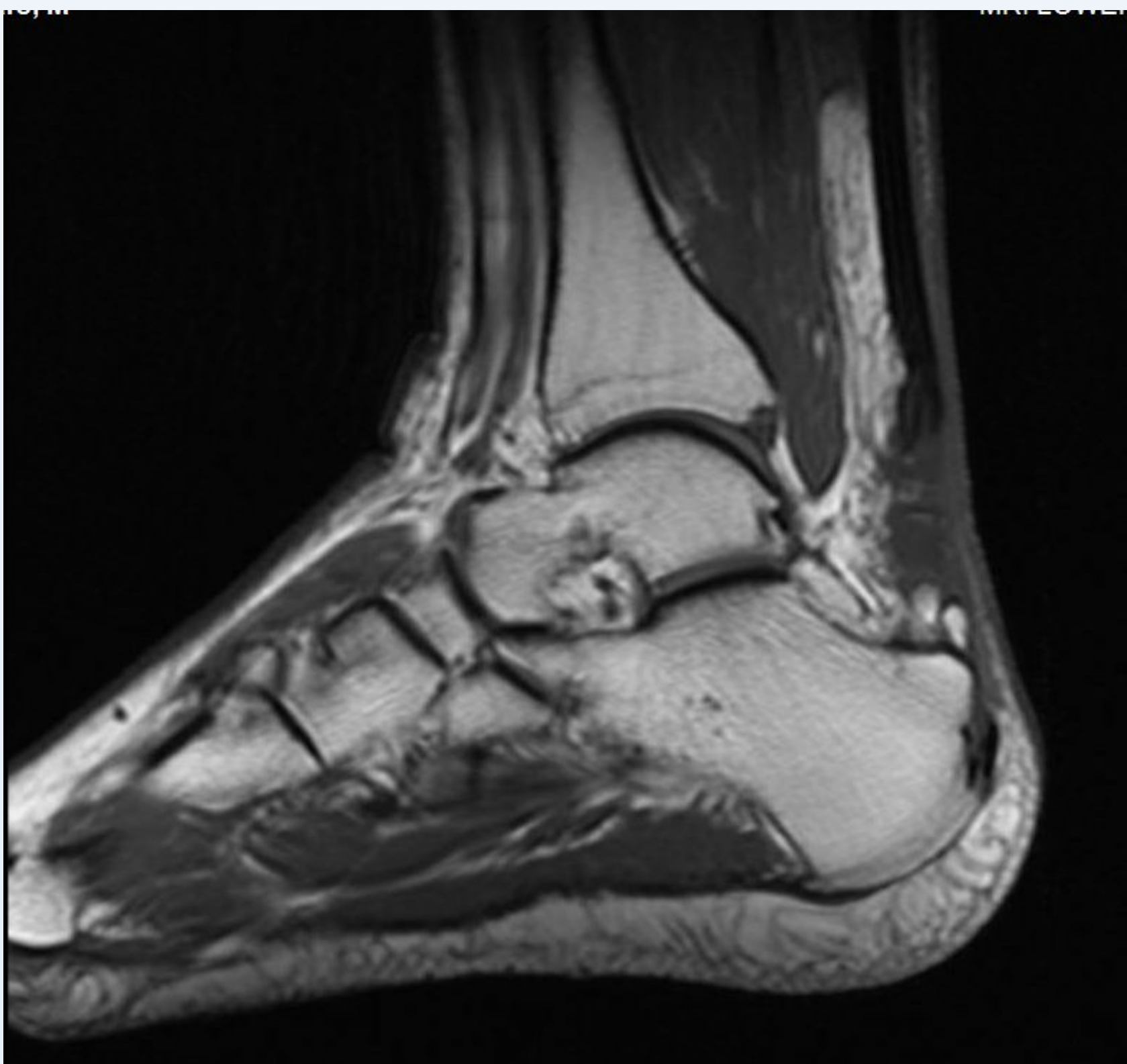
Alkaptonuria, with it's sequelae of ochronosis, is a rare hereditary metabolic disease characterized by the accumulation of homogentisic acid in connective tissues such as the tendons, cartilage, heart valves and skin. The term 'ochronosis' is named after the yellowish (ochre-like) discoloration of the tissues on microscopic examination. Macroscopically, the affected tissues have been described to have a dark bluish grey appearance. It has an incidence of 1:125,000 to 1:1,000,000 worldwide. In the present study, we report the presentation and surgical treatment of a patient with spontaneous Achilles tendon rupture, a complication of ochronosis. To our knowledge, this is the first case report from the United States describing successful salvage of an Achilles tendon rupture in the setting of alkaptonuria.

Pre-operative Imaging

Figure 1 (Mar 2015)
Plain radiograph (left) demonstrating obliteration of the margin's of Kager's triangle.
T2 weighted magnetic resonance Imaging (right) demonstrating complete rupture of the Achilles tendon and approximately 5cm of retraction from it's insertion

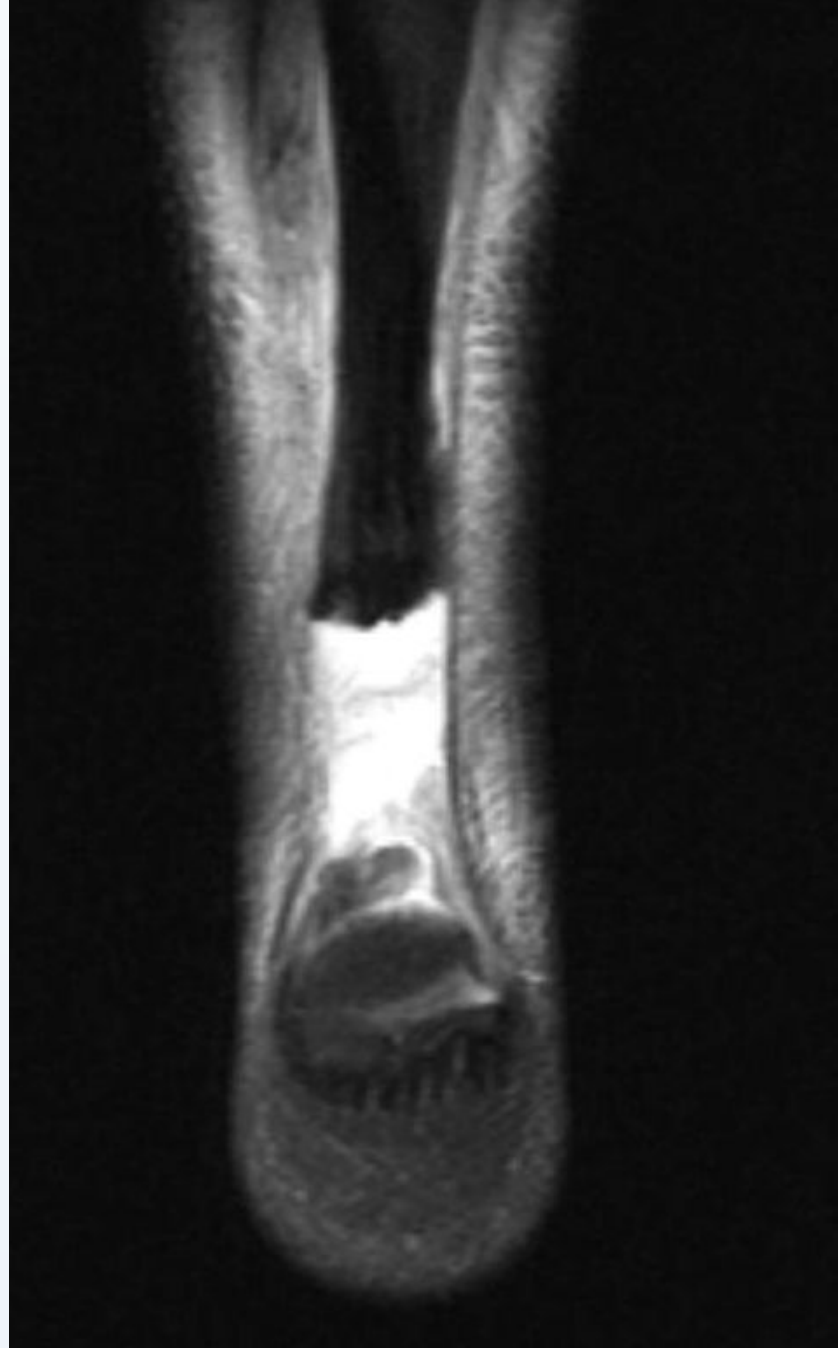
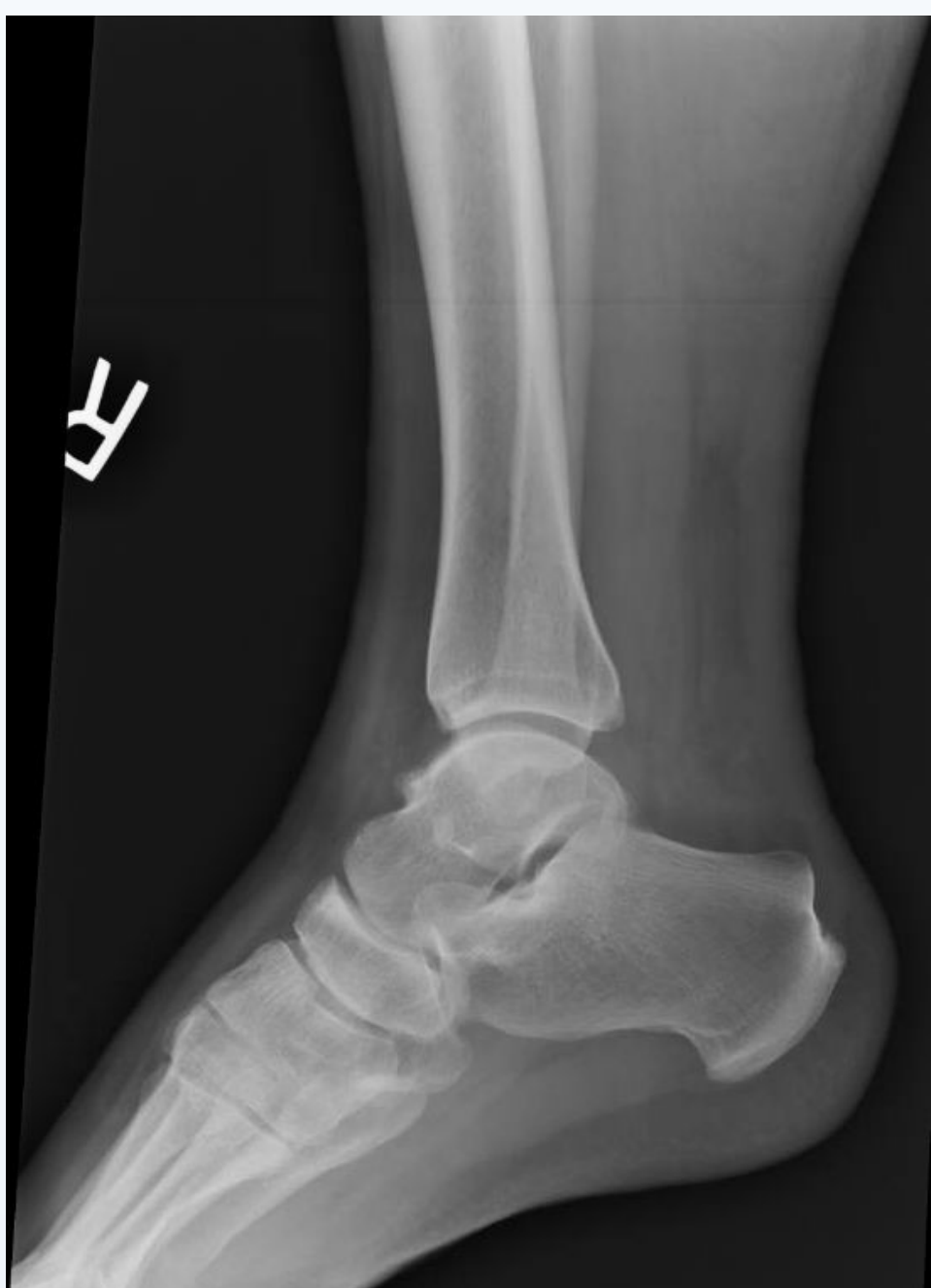
Figure 2. (March 2015)
T1 weighted magnetic resonance imaging demonstrating complete rupture of the Achilles tendon and approximately 5cm of retraction from it's insertion on the calcaneus.



Case Study and Procedure 1 of 2

A 38 year old male with a history of alkaptonuria presented complaining of pain and swelling in his right rearfoot sustained while he was stomping on ice ten days prior. The patient also endorsed a history of being a toe-walker his entire life. On examination he did have diffuse swelling over the posterior aspect of ankle with a palpable defect over the Achilles tendon proximal to it's insertion. The discontinuity of the Achilles tendon was confirmed by the inability to stand on his toes and by the Thompson "squeeze" test. On the lateral view radiograph of the ankle, the superior and inferior margins of the Kager's triangle were poorly defined, consistent with abnormal increased density. Magnetic resonance imaging revealed that the Achilles tendon was completely torn and retracted approximately 5cm.

The patient subsequently elected to undergo open repair of his Achilles tendon, however, intra-operative findings revealed that the distal stump was insufficient for primary repair. The severed stumps of the Achilles tendon were also found to have dark pigmentation and were highly indurated to a consistency similar to that of rubber. The distal stump was subsequently excised along with the darkened and rubbery tip of the proximal stump. The decision was made to proceed with transfer of the flexor hallucis longus tendon to the posterior aspect of the calcaneus.

Case Study and Procedure 2 of 2

This was performed by a short harvest technique and fixation using a 7 x 23mm biotenodesis screw (Arthrex) which was reinforced with a sterile button and felt pad on the plantar aspect of the foot. A gastrocnemius recession was performed and the muscle belly subsequently advanced distally for myodesis to the transferred flexor hallucis longus for additional strength and vascularity. After irrigation and a layered skin closure, the patient was placed in well padded Jones compression bandage and posterior splint, taking care to maintain the ankle in about 20 degrees of equinus.

Intra-operative Images

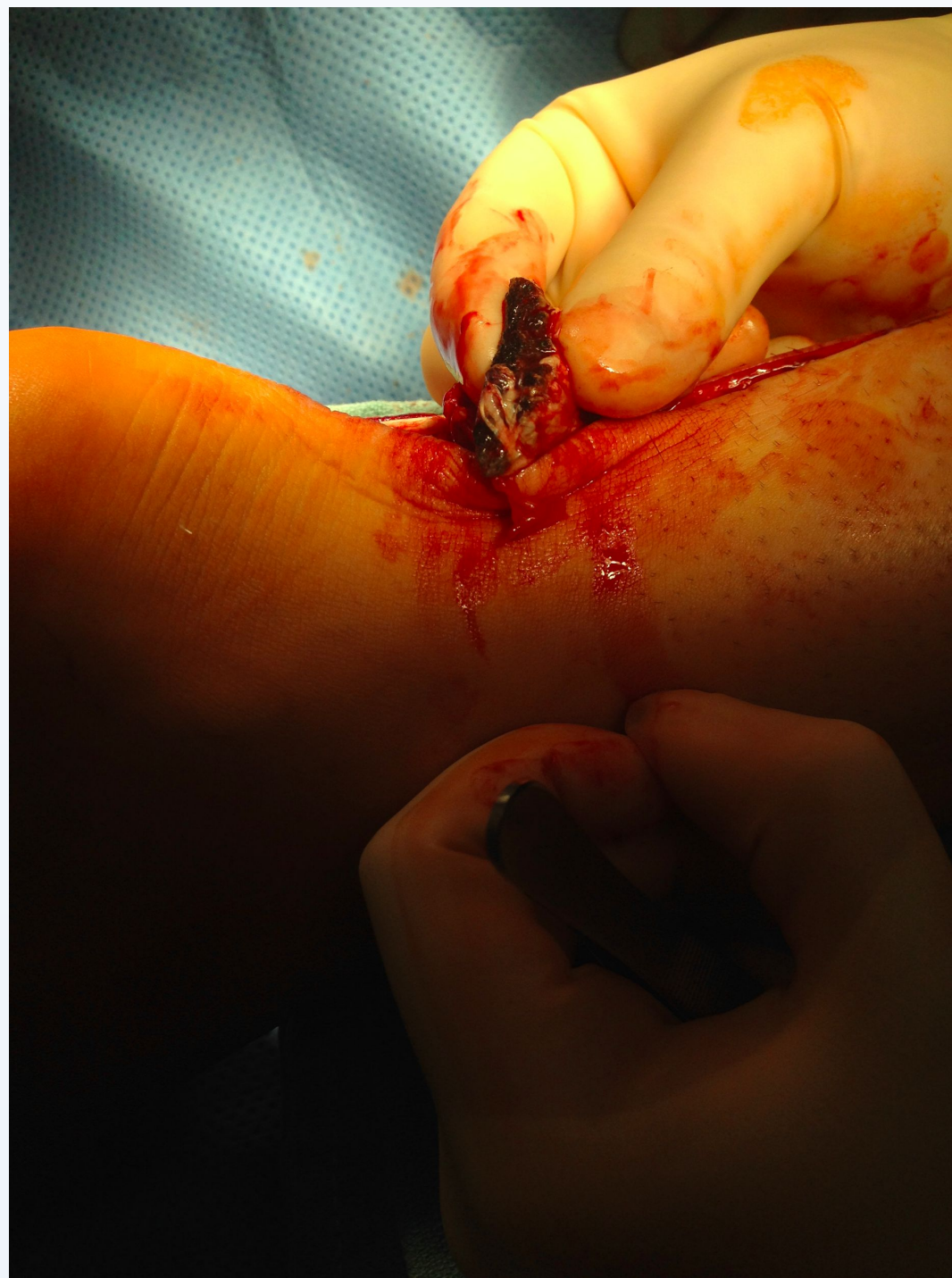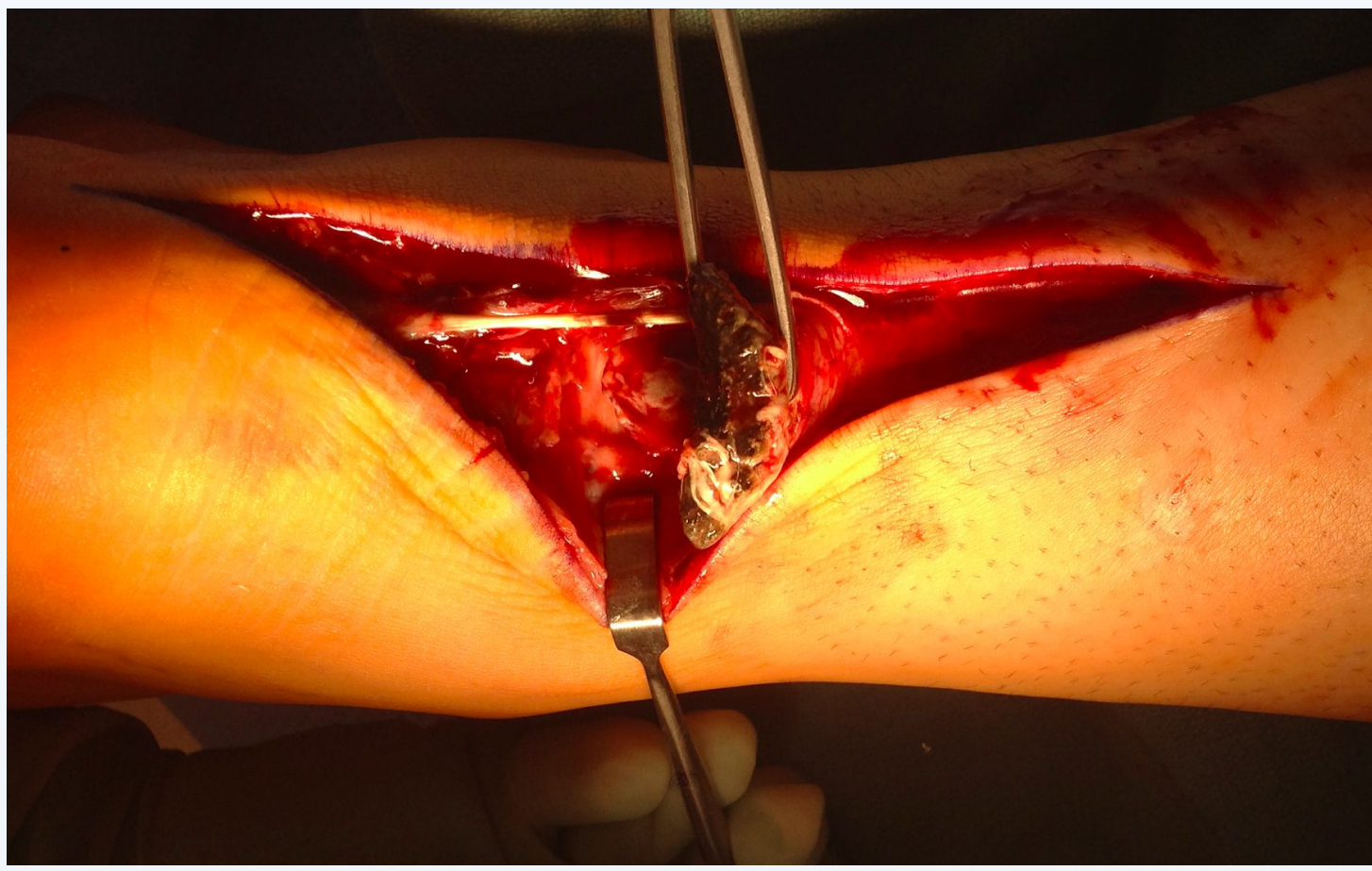
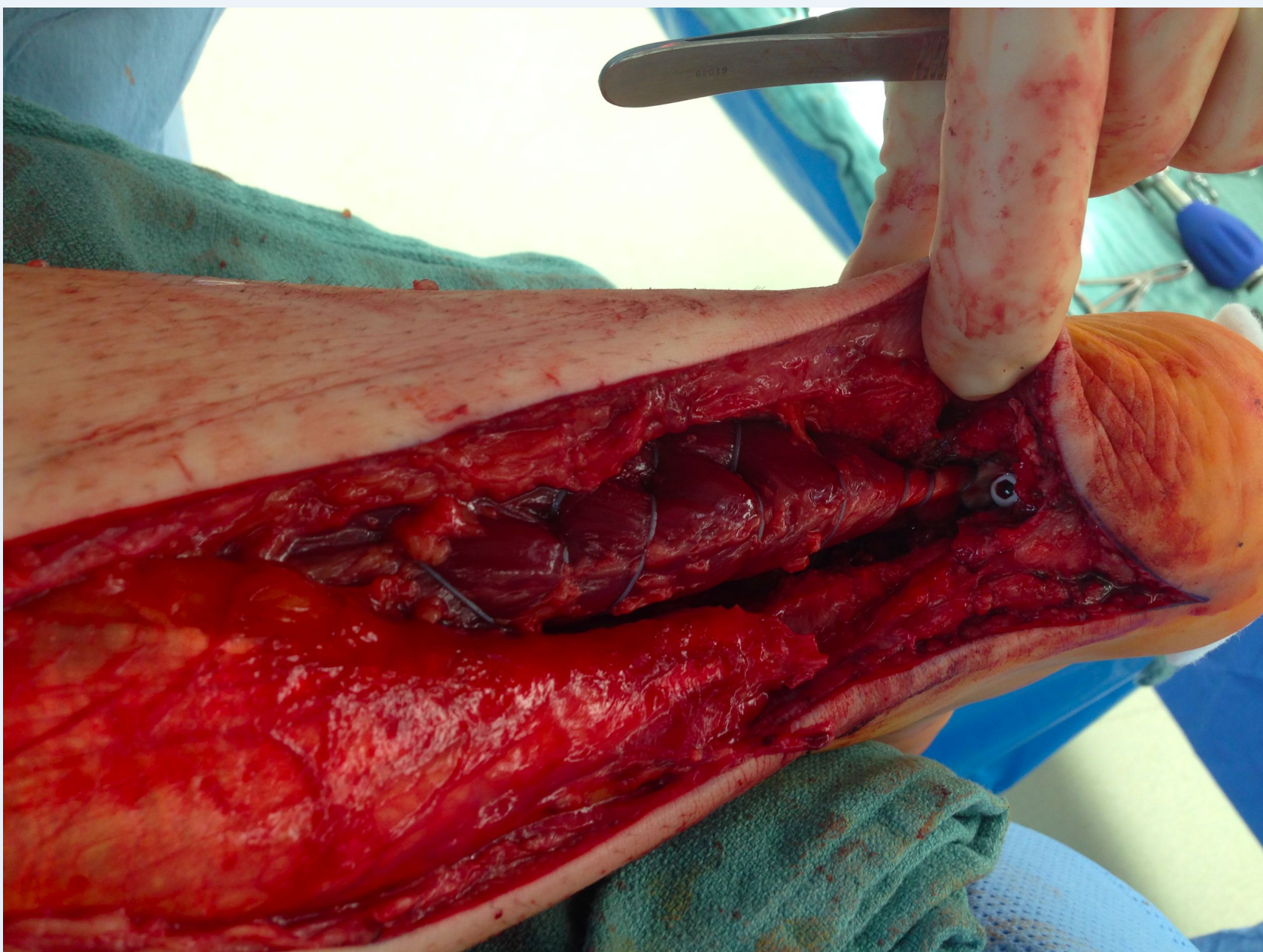


Figure 3 (above) the darkly discoloured proximal stump of the ruptured Achilles tendon being grasped by the Allis clamp

Figure 4 (above right) the diseased tendon was excised

Figure 5 (below) visualization of the FHL tendon transfer and myodesis of the gastrocnemius muscle belly



Post Operative Course

At 4 weeks, the surgical wound had healed and the sutures removed. The suture button was removed at the 8 week post operative visit. After a total of 12 weeks in a non weight-bearing short leg cast, the patient was transitioned into a CAM boot and allowed to start range of motion exercises. At the 5 month post-operative visit, the patient was allowed to begin transition to low impact weight-bearing activities as tolerated. The patient's post-operative course has since been quite uneventful. At his 3-year post-operative visit, the patient endorsed satisfaction with the procedure and has since committed himself to physical therapy and exercise in order to improve his general health and well-being. He reported no pain with ambulation and a successful return to normal weight-bearing activities of daily living.

Discussion

Patients with alkaptonuria are commonly asymptomatic until the third decade of life. However, by the second decade, a bluish gray pigmentation can appear in the sclera, cartilage of the ear and in the teeth, buccal mucosa and in the nails or skin. These manifestations are the result of irreversible binding of homogentisic acid in the fibrillary collagen of connective tissues by polymerization and oxidation. The deposits can make the connective tissue rigid and usually lead to joint degeneration in the axial and appendicular skeleton by the fourth decade of life. Spontaneous tendon ruptures are quite a common occurrence in these patients. These patients frequently present with tendo Achilles ruptures as the first clinical manifestation. In 2004, a worldwide review found that approximately 600 cases of ochronotic arthropathy have been reported since 1962.

The goal of the procedure was to restore the active function of the ankle joint and minimize the chance of re-rupture in this patient whose medical history of alkaptonuria presented unique challenges. With no specific treatment for ochronosis, efforts at treatment are targeted at minimizing the damaging effects of the underlying metabolic disorder on the articular cartilage and tendons. Dietary reduction of phenylalanine and tyrosine in encourage. Administration of vitamin C, vitamin E and N-acetyl cysteine is thought to retard the conversion of the homogentisic acid to the polymeric material by harnessing their antioxidant properties

Special care should be taken of these patients in the peri-operative setting due to their associated comorbidities. Careful positioning and padding of the pressure points should be considered to avoid triggering pain and other affected joints. Preoperative neurological examination and navigation of difficult regional blocks should be considered given degenerative changes in the spine that is common in these patients. For this reason it is recommended to fully evaluate the patient extent of systemic dysfunction when determining the appropriate intraoperative anesthetic technique as part of the pre-operative workup for patients affected by this condition.

References

1. Lai M, Thankur M, Kashyap S, Alkaptonuric ochronosis, Orthopedics, 2014;37:e1141-e1149
2. Mirzashahi B, Tafakhori A, Najafi A, Farzan M, Neglected Alkaptonuric Patient Presenting with Steppage Gait, Arch Bone Jt Surg. 2016; 4(2): 188-191
3. Shetty S, Sankar R, Babu B, Matthias L, Bhat S, Rai R, Spontaneous Achilles Tendon Rupture - A Case of Ochronosis, NUJHS Vol3, September 2013, ISSN 2249-7110
4. Rao J, Achilles tendon enthesopathy in ochronosis, J Postgrad Med March 2006 Vol 52 Issue 1
5. Gil J, Wawrzynski J, Waryasz G, Orthopedic Manifestations of Ochronosis: Pathophysiology, Presentation, Diagnosis and Management, The American Journal of Medicine Jan 2016
6. Roberts N, Curtis S, Milan A, Ranganath L, The pigment in alkaptonuria relationship to melanin and other colored substances colon a review of metabolism, composition and chemical analysis, JIMD Reports, DOI 10.1007/8904_2015_453
7. Ventura-Rios L, Hernandez Diaz C, Guierrez-Perez L, Bernal-Gonzalez A, Pichardo-Bahena R, Cedeno-Garciduenas L, Pineda C, Ochronotic arthropathy as a paradigm of metabolically induced degenerative joint disease. A case-based review. Clin Rheumatol (2016) 35:1389_1395
8. Millici L, Giorgetti G, Viti C, Ghezzi L, Gambassi S, Braconi D, Marzocchi B, Paffetti A, Lupetti P, Bernardini G, Orlandini M, Santucci A, Chondroptosis in Alkaptonuric Cartilage, Journal of Cellular Physiology 230: 148-157, 2015
9. Pandey R, Kumar A, Garg R, Khanna P, Darlong V, Perioperative management of patients with alkaptonuria and Associated multiple comorbidities, Journal of anesthesiology clinical pharmacology. 2011;27:259-261