

# Angioleiomyoma: Surgical Resection of a Rare Tumor

Dr. Billy Martin, DPM, Dr. Brian Hiapo, DPM, Dr. Kendra Anderson, DPM, Jordan Vogt, MS4

Southern Arizona VA Healthcare System

## Introduction

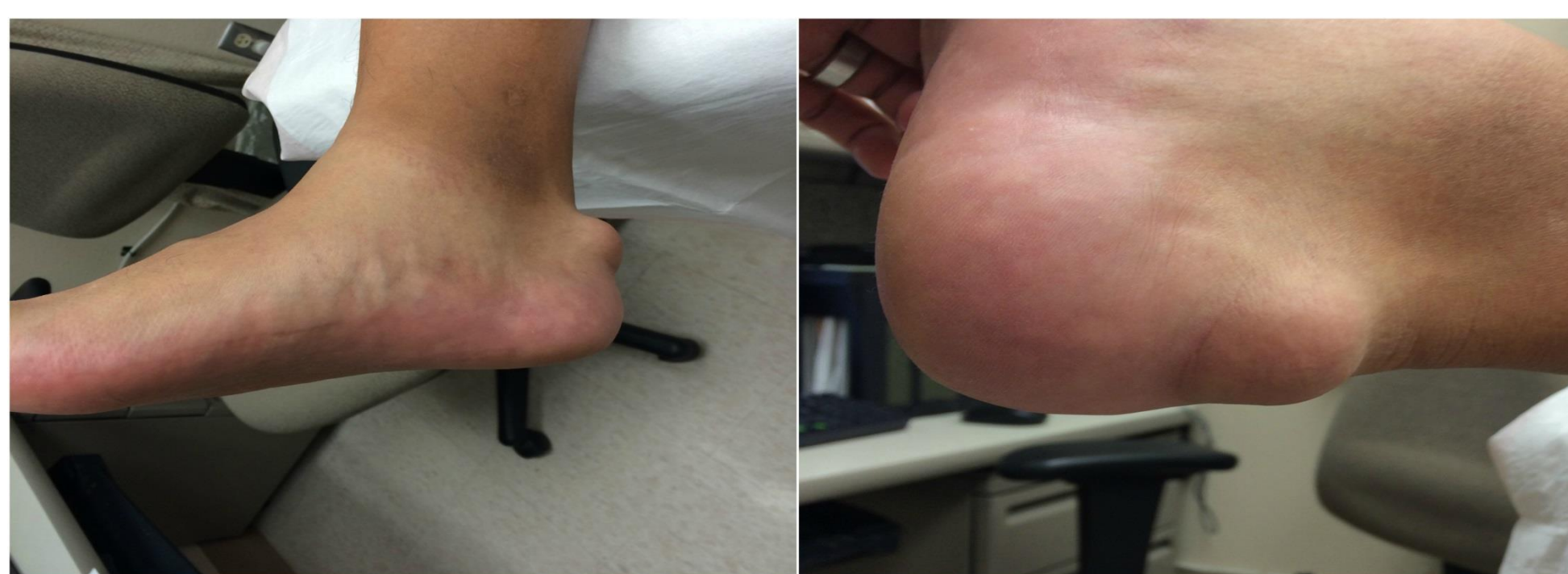- Angioleiomyoma is a benign soft tissue tumor arising from vascular smooth muscle that presents commonly between the third and fifth decades of life.
- This tumor has a predilection for middle-aged women and it is most often seen in the extremities, particularly in the lower leg.
- Angioleiomyomas account for 5% of all benign neoplasms of the soft tissues. It presents as a painful mass in approximately 60% of the cases.
- A distinct clinical feature is increased size and swelling of the mass during physical activity of the involved location.
- Consideration should be given to angioleiomyoma when creating a differential diagnosis for painful nodular lesions of the extremity. Pre-operative diagnosis can be difficult, but having a high index of suspicion and general awareness of this lesion makes it possible.
- The use of ultrasound and magnetic resonance imaging should be considered.
- It causes minimal morbidity and excision is usually curative.

## Presentation

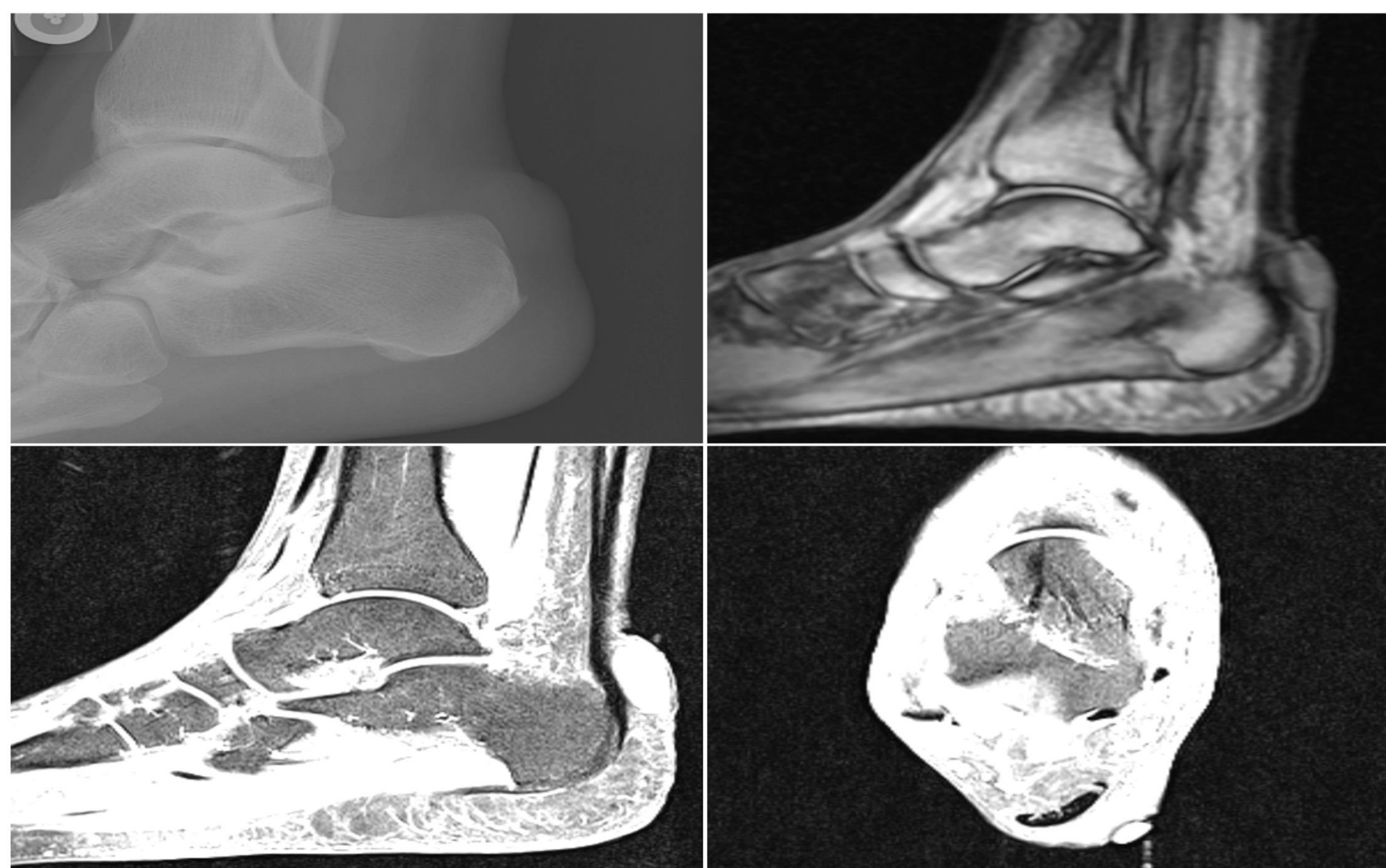
### 8/16/16 – New Patient Consult

- Patient is a 42 year old non-DM2 Male who presents as a consult for right posterior heel pain and mass x 11 years. The painful mass is located at the right posterior heel. States that the mass at the back of the heel has increased in size over the past years and is painful in any type of shoe gear. Patient denies any knowledge of initiating event to the mass. Patient describes the pain as a sharp 8/10 pain that is localized to the posterior heel and that the pain improves when not wearing shoes and worsens with wearing shoe gear. Patient denies any prior treatment or taking any medication.

## Clinical Images



## Imaging



(7/14/16 Plain Radiographs) - Impression: Significant soft tissue prominence in the vicinity of the distal Achilles tendon.

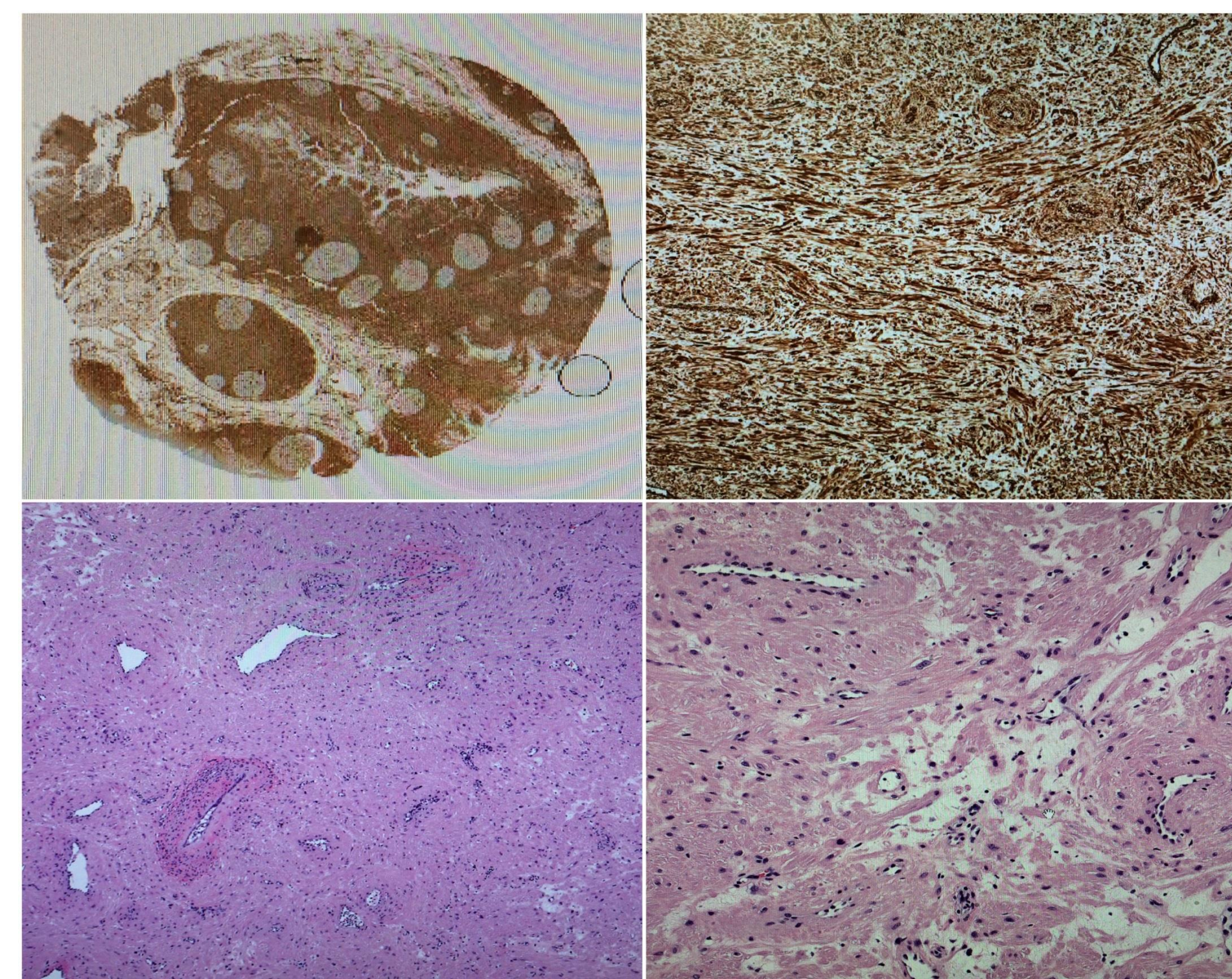
(10/1/16 Magnetic Resonance Imaging) - There is a well-defined mass in the subcutaneous tissues superficial to the distal Achilles tendon measuring 2.6 cm in left-right, 2.5 cm in cephalocaudal-caudal, and 9 mm in AP (thickness) dimensions. This mass is intermediate on T1 and increased on T2 signal intensity. Possible Malignancy

### 10/20/16 – Fine Needle Aspiration

- Fine Needle Aspiration performed by the Pathology Department at this visit. The report: The smears contain only a few bland-appearing cells of uncertain origin. Neoplasms of soft tissue origin often fail to yield sufficient material for diagnosis via fine needle aspiration.

### 11/18/16 – Surgical Resection and Pathology

- Encapsulated adhered soft tissue mass removed from the right posterior heel. Tourniquet time was 40 minutes with no complications experienced.
- *Pathology Gross description:* A well-circumscribed, rubbery firm mass measuring 2.7 x 2.5 x 1.1 cm. The cut surface is homogeneous without areas of hemorrhage or necrosis.
- *Microscopic exam/diagnosis:* Benign spindle cell tumor with features of deep fibrous histiocytoma
- *Comment:* The tumor shows benign-appearing spindle cells within a fibrous stroma with hemangiopericytoma-like vascular pattern. No tumor necrosis or mitotic activity is detected. On immunostaining, tumor cells are diffusely positive for vimentin and actin. Some tumor cells are also positive for CD68 marker. Based on these features and its location, we favor a deep benign fibrous histiocytoma consistent with the diagnosis: Angiomyoleioma.

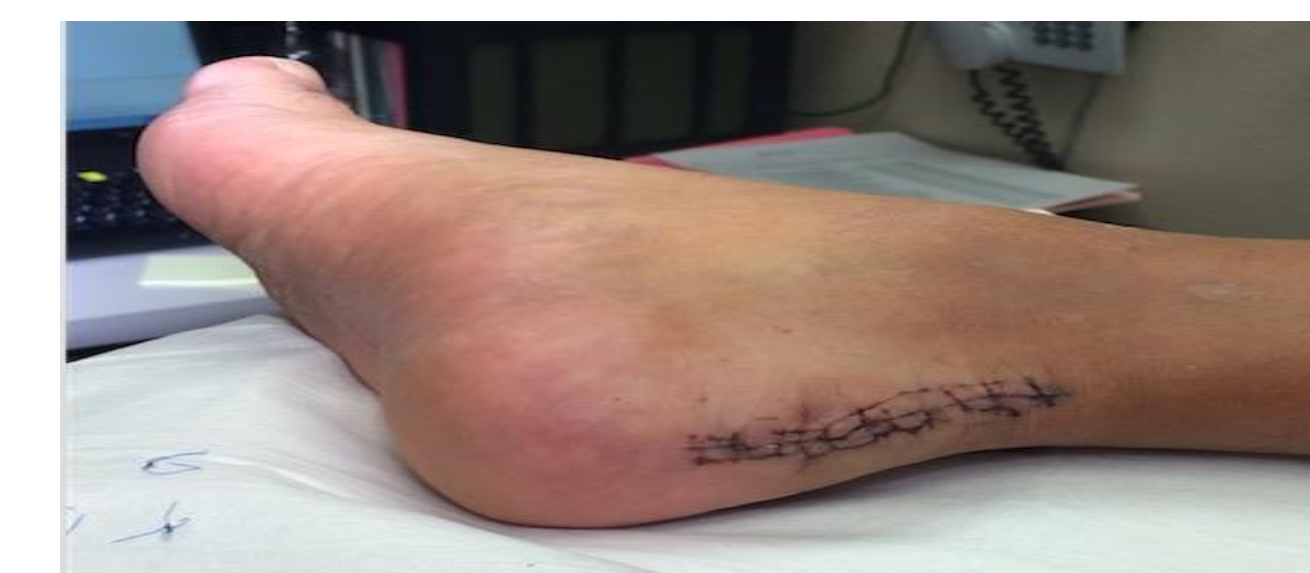

### 11/21/16 – Post Op Visit #1

- Minimal pain and swelling consistent with routine post-operative course

### 12/1/16 – Post Op Visit #2

- No pain and very minimal swelling. Sutures removed and skin edges are well-coapted. All signs of tumor removed without any recurrence



## Bibliography

1. Ramesh, P., S.r. Annapureddy, F. Khan, and P.d. Sutaria. "Angioleiomyoma: A Clinical, Pathological and Radiological Review." *International Journal of Clinical Practice* 58.6 (2004): 587-91. Web.
2. Baarini, Omar. "Angioleiomyoma of the Plantar-Medial Arch: A Case Report." *Journal Of Clinical And Diagnostic Research* (2016): n. pag. Web.
3. Cheung, M.-H. S., and T.-H. Lui. "Plantar Heel Pain Due to Vascular Leiomyoma (Angioleiomyoma)." *Foot & Ankle Specialist* 5.5 (2012): 321-23. Web.
4. Lai, Alta Yt, Cw Tam, John Sf Shum, Jennifer Ls Khoo, and Wl Tang. "Magnetic Resonance Imaging Features of Vascular Leiomyoma of the Ankle." *Hong Kong Medical Journal* (2015): 73-76. Web.
5. Hamoui, Mazen, Arnaud Largey, Mazen Ali, Patrick Fauré, Olivier Roche, Wayan Hebrard, and François Canovas. "Angioleiomyoma in the Ankle Mimicking Tarsal Tunnel Syndrome: A Case Report and Review of the Literature." *The Journal of Foot and Ankle Surgery* 49.4 (2010): n. pag. Web.
6. Requena, Luis, and Robert Baran. "Digital Angioleiomyoma: An Uncommon Neoplasm." *Journal of the American Academy of Dermatology* 29.6 (1993): 1043-044. Web.
7. Hachisuga, Tooru, Hiroshi Hashimoto, and Munetomo Enjoji. "Angioleiomyoma. A Clinicopathologic Reappraisal of 562 Cases." *Cancer* 54.1 (1984): 126-30. Web.