

P. Tanner Shaffer, DPM, Brian J. Burgess, DPM, FACFAS, Joseph Wilson, DPM, Curt Martini, DPM
 Mercy Hospital and Medical Center Chicago, Illinois 60616

PURPOSE

The purpose of this study was to examine screw presence in the fifth metatarsal-cuboid joint after intramedullary screw fixation of acute Jones fractures using the traditional “high and inside” technique

LITERATURE REVIEW

A Jones fracture is described as a fracture in the fifth metatarsal at the metaphyseal-diaphyseal junction. Sir Robert Jones is credited with the original description after he suffered this type of fracture while dancing. While Jones fractures can often occur in all foot types, studies have shown the presence of metatarsus adductus carries a 2.4 x greater risk for suffering a Jones fracture¹. Both conservative vs. surgical fixation of these fractures have been debated in the literature. Of the surgical options available, percutaneous intramedullary (IM) single screw fixation has been shown to be an effective technique in treatment of Jones fractures.² The most common complications following acute Jones fracture repair using IM screw fixation include delayed or non-union, refracture, prominent screw head, and sural nerve injury.³

CASE SERIES

Forty-five patients who underwent IM screw fixation of acute Jones fractures were included in this retrospective case series. The surgical technique is as follows: The “high and inside” starting position was used for placement of an intramedullary screw on the fifth metatarsal base under fluoroscopic guidance. After the intramedullary canal was prepared with a cannulated drill and tap, the solid screw was inserted in traditional manner. Post-operative x-rays from surgery were all retrospectively reviewed by an independent, radiologist. Standard weight-bearing AP, lateral, and oblique films were examined to determine the presence of the screw within the fifth metatarsal-cuboid joint, defined as disruption of the articulating surfaces with any part of the screw. The percentage of patients with intra-articular joint involvement of the fifth metatarsal-cuboid joint was then reported.

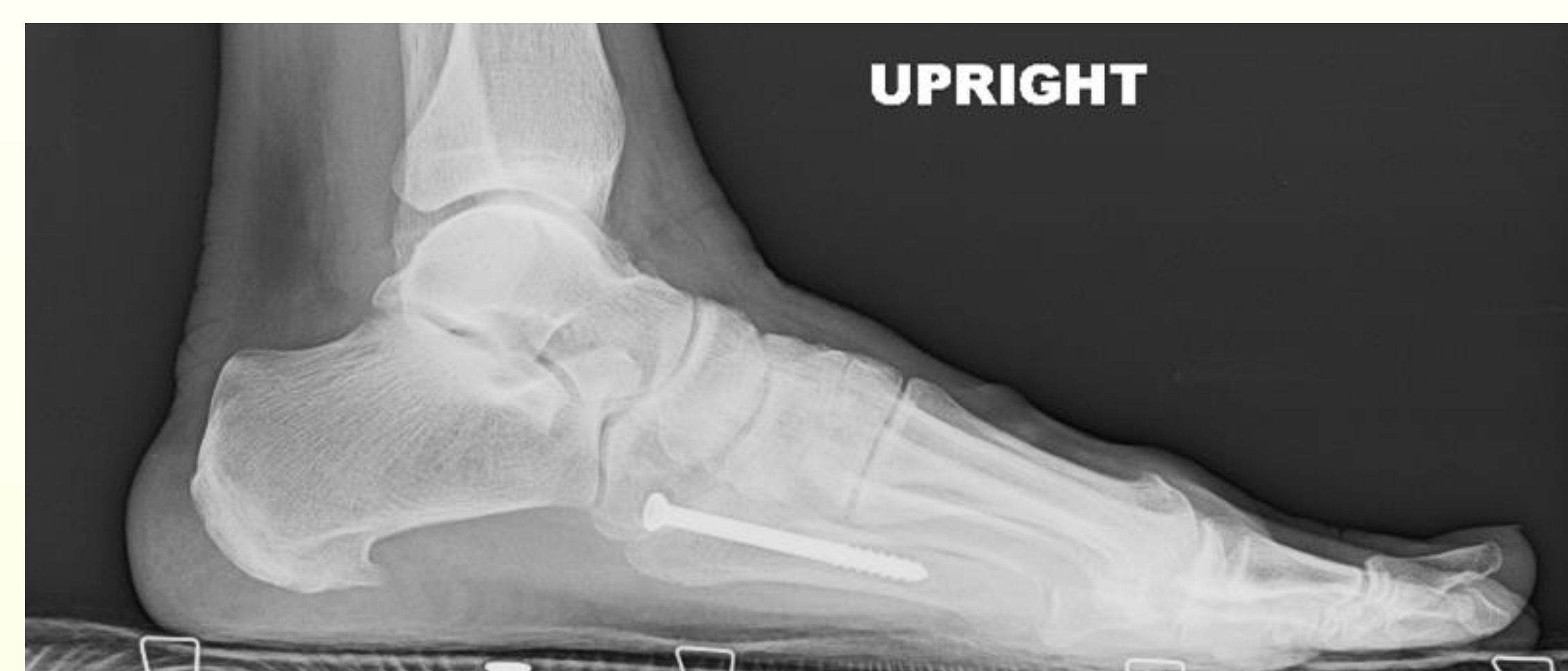ANALYSIS

Forty-five patients (14 men and 31 women) who underwent IM screw fixation of acute Jones fractures by a single surgeon were reviewed for their radiographic outcomes at final post operative visits. Of those 45 patients, 20 (44.4%) were found to have intra-articular presence of the screw in the fifth metatarsal-cuboid joint. Of note, 11 (24.4%) of cases graded as “no joint violation” on first look were changed to “joint violation” on second look by our radiologist. Only 1 case (2.2%) was changed from “no violation” to “joint violating” in our study population.

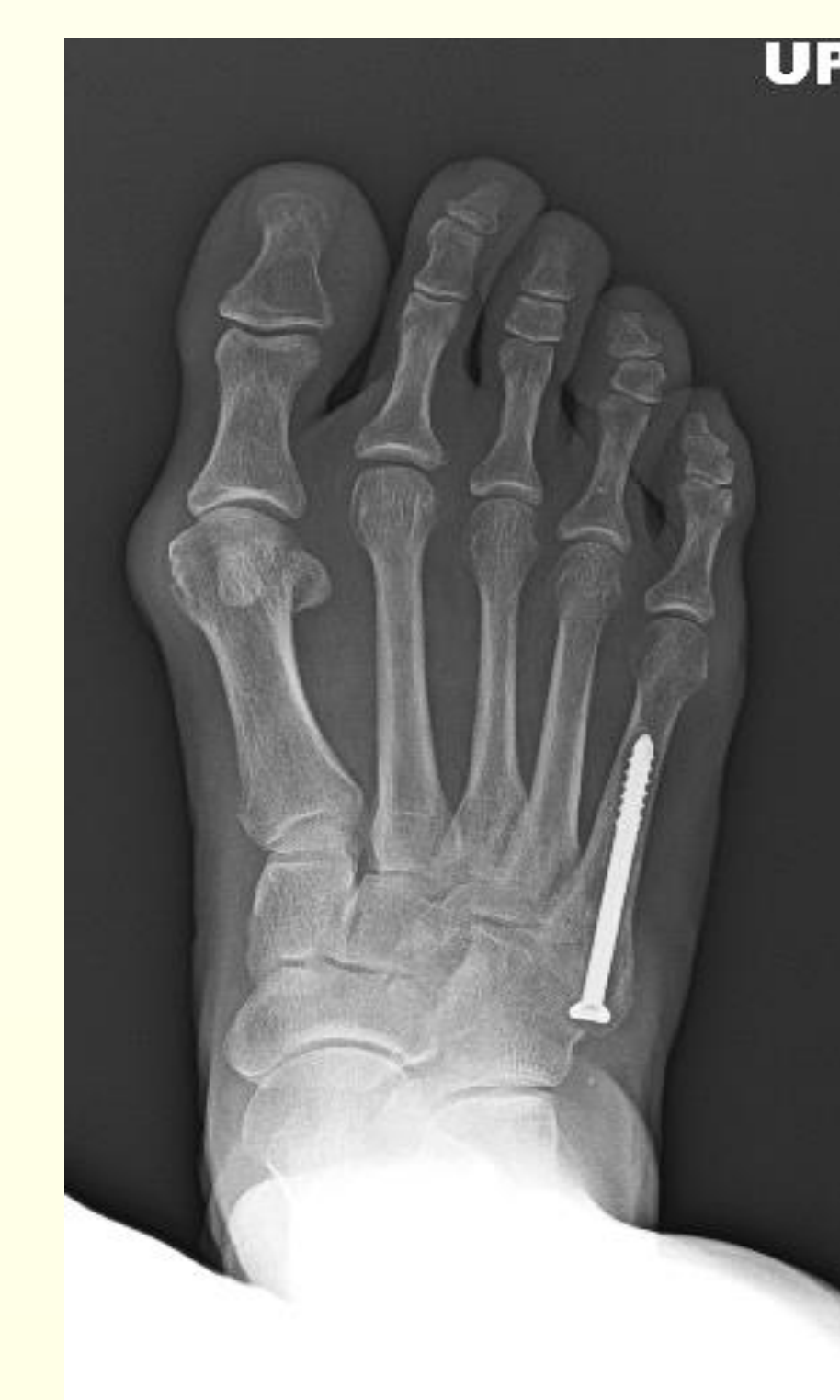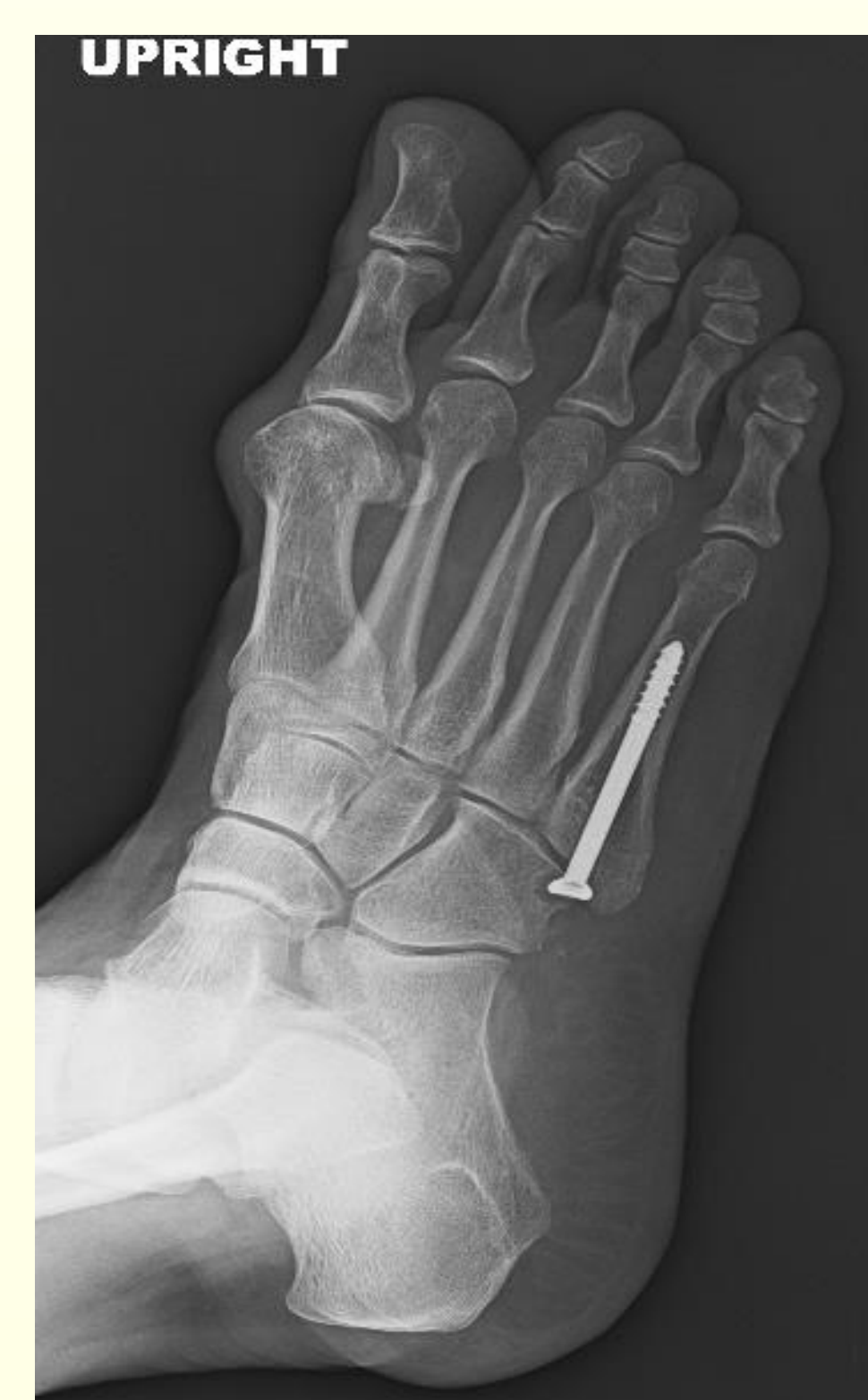DISCUSSION

To our knowledge, no study to date has described the incidence of screw presence in the fifth metatarsal-cuboid joint after IM screw fixation for acute Jones fractures using the traditional “high and inside” technique. 5.5mm solid stainless-steel screws were used in our patient population due to their high pull out strength, and high fatigue resistance.⁴ Our study shows that 20 of the 45 patients (44.4%) had screw penetration into that joint. Some possible causes of this could be the shape and amount of bowing of the 5th metatarsal, which has been shown to strongly correlate with patient height,⁵ and an increased 4-5 IM angle or decreased met adductus/cuboid 5th metatarsal angle (requiring excess ‘hugging’ of the foot/TMTJ to throw the screw down the medullary canal). While the clinical importance of this is not completely known, we believe that it could be a source of persistent post-operative pain, discomfort and swelling even after fracture healing has occurred. Multiple cases in our study show lucency in the cuboid from violation of the screw head. Future studies should include long term follow up with documentation of persistent irritation, progressing degenerative joint disease, and the need for screw removal in patients with intramedullary screw fixation that may violate the fifth metatarsal cuboid joint

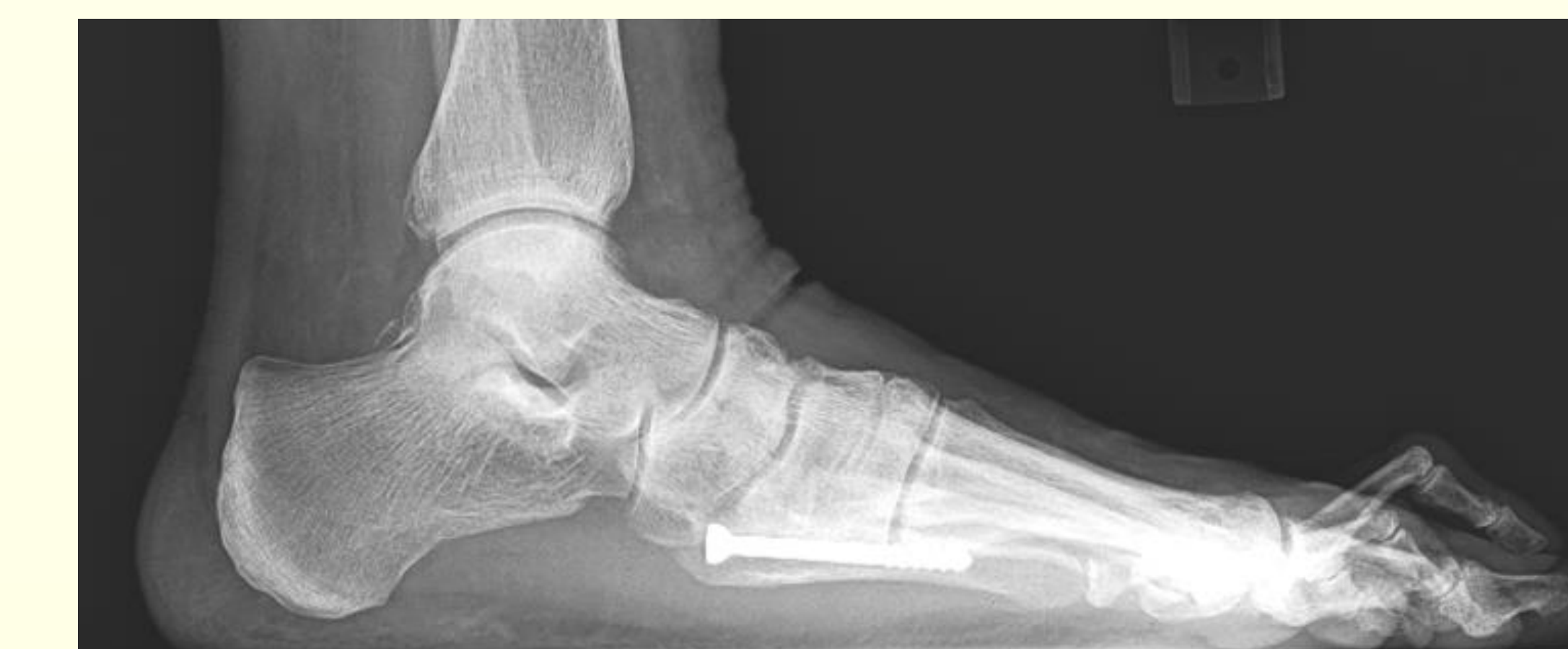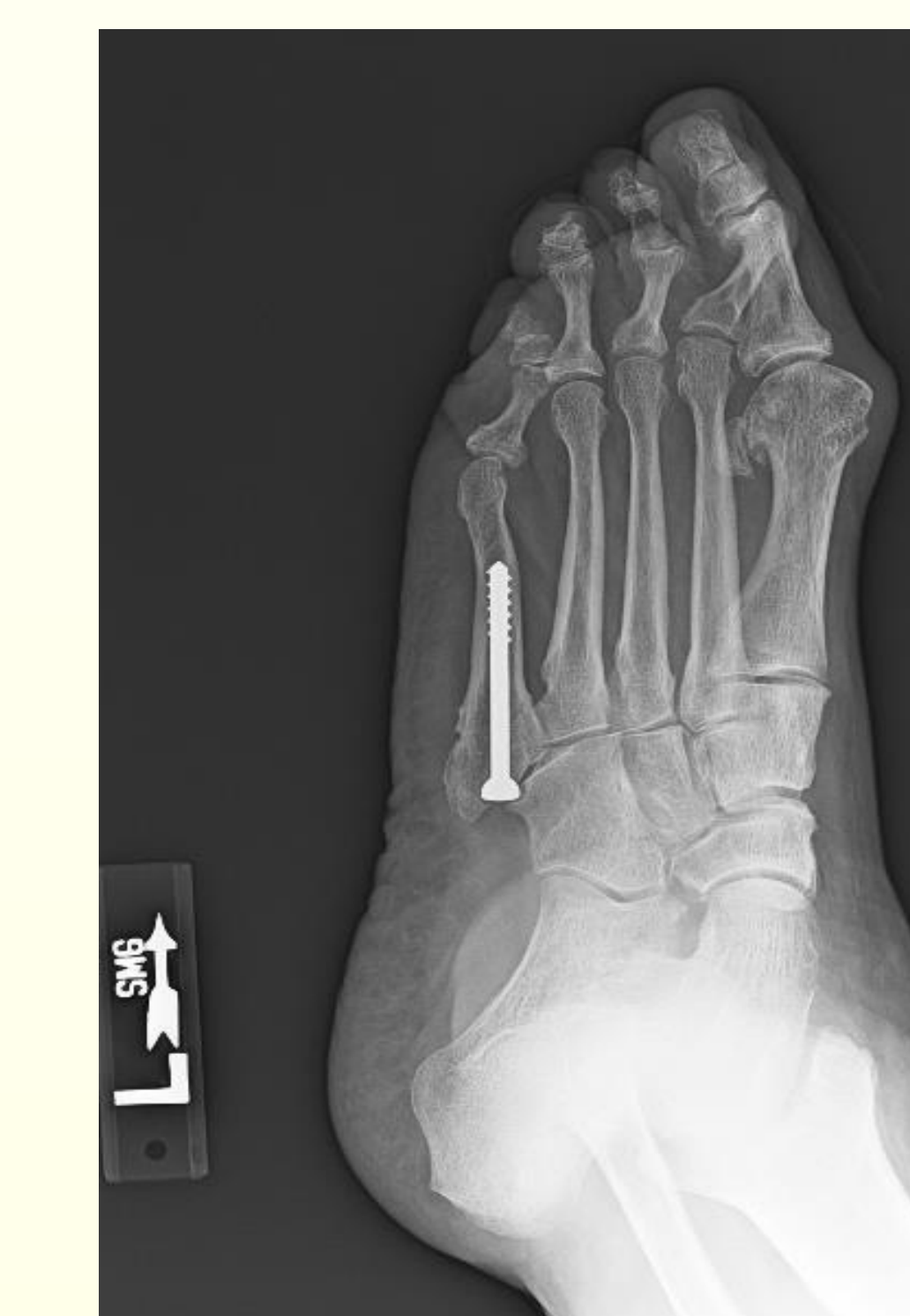
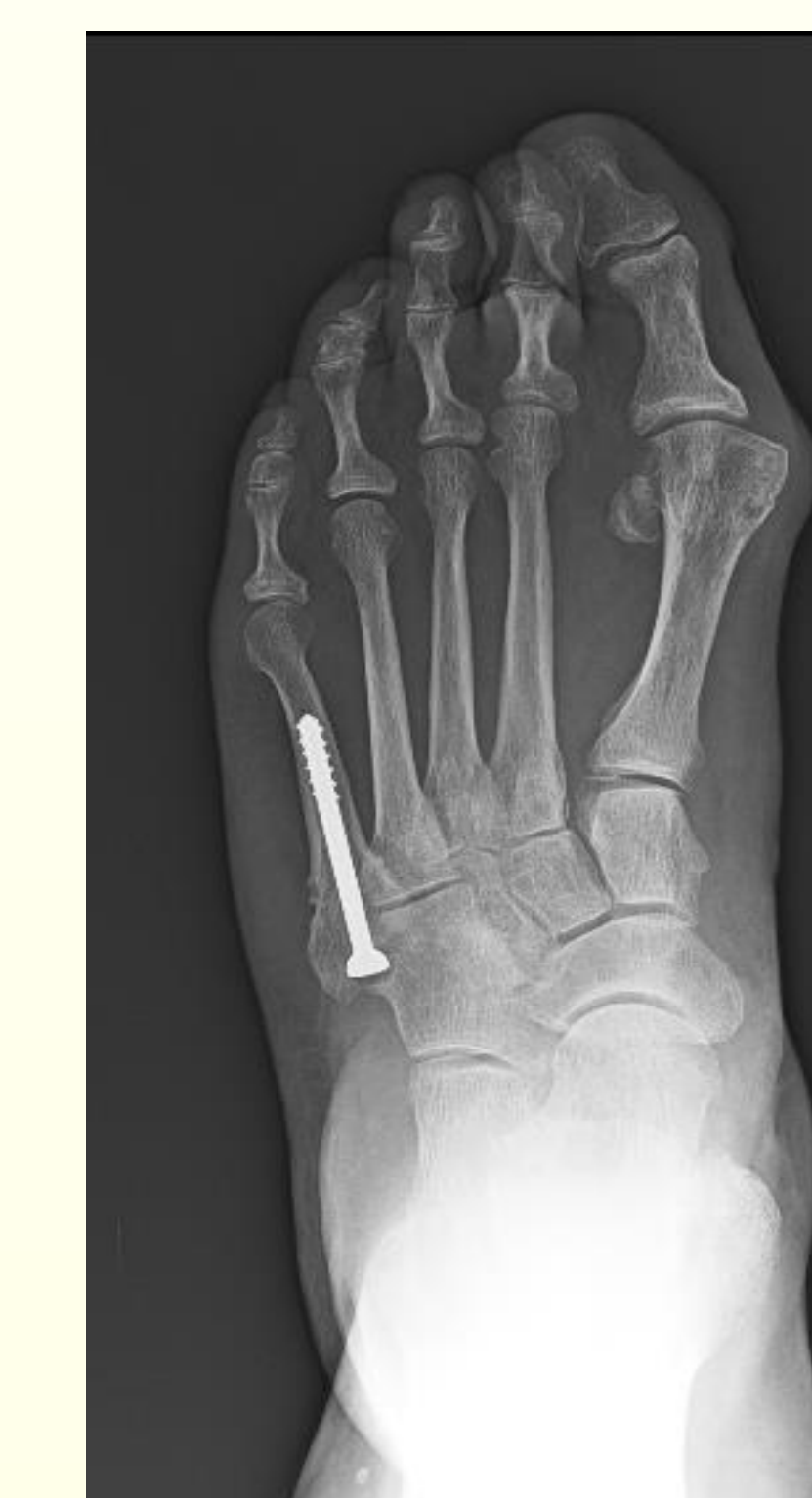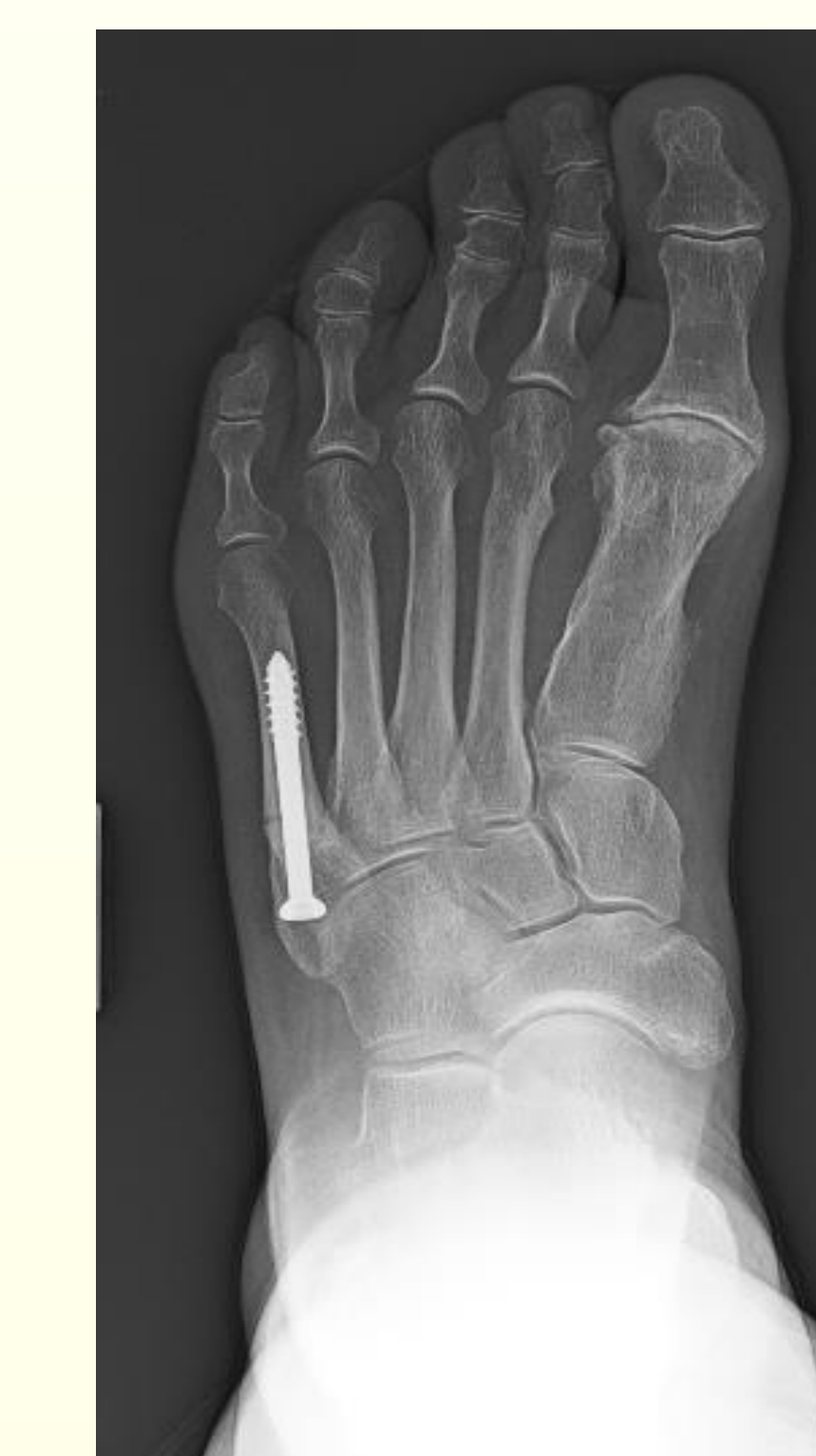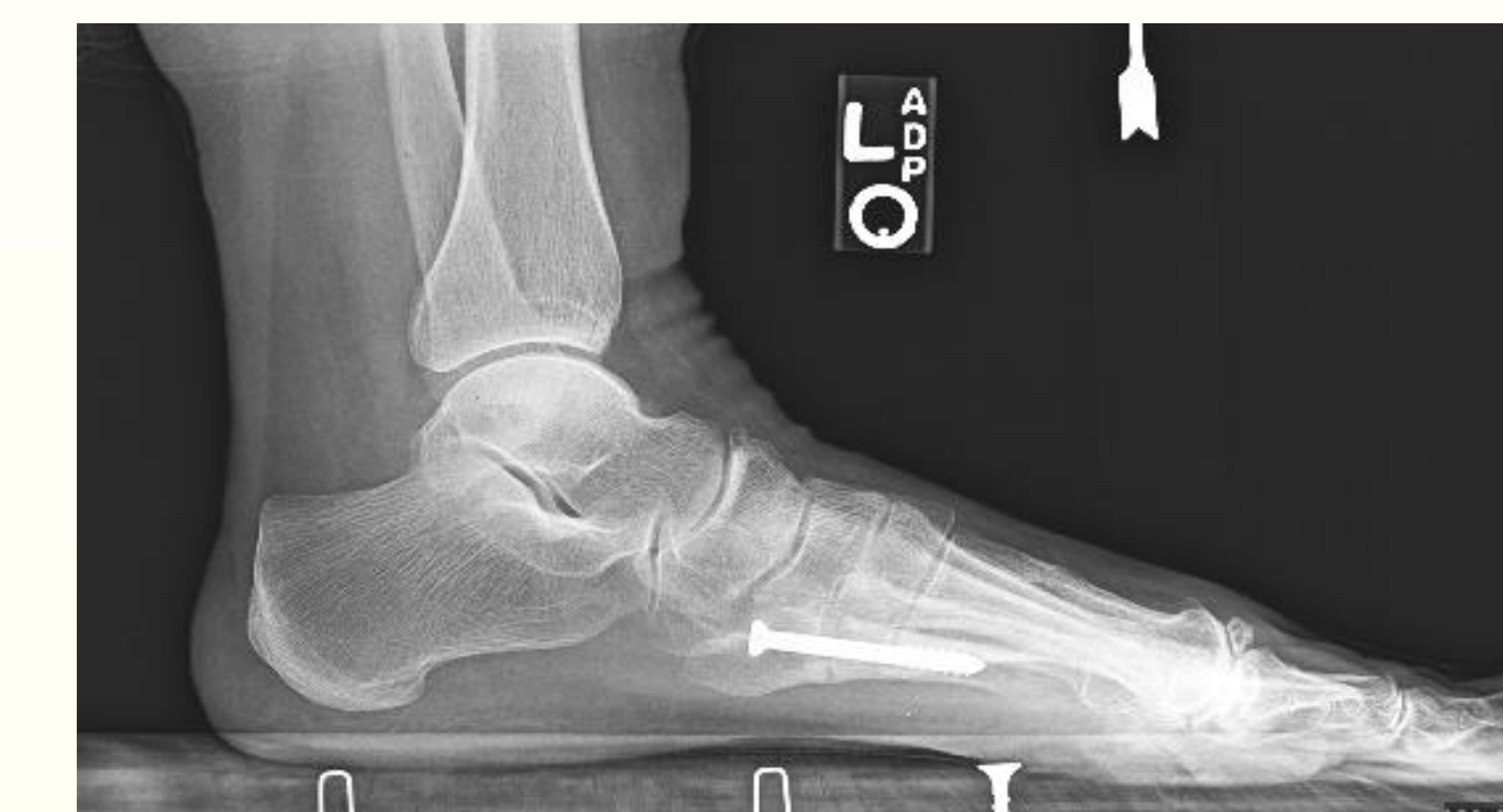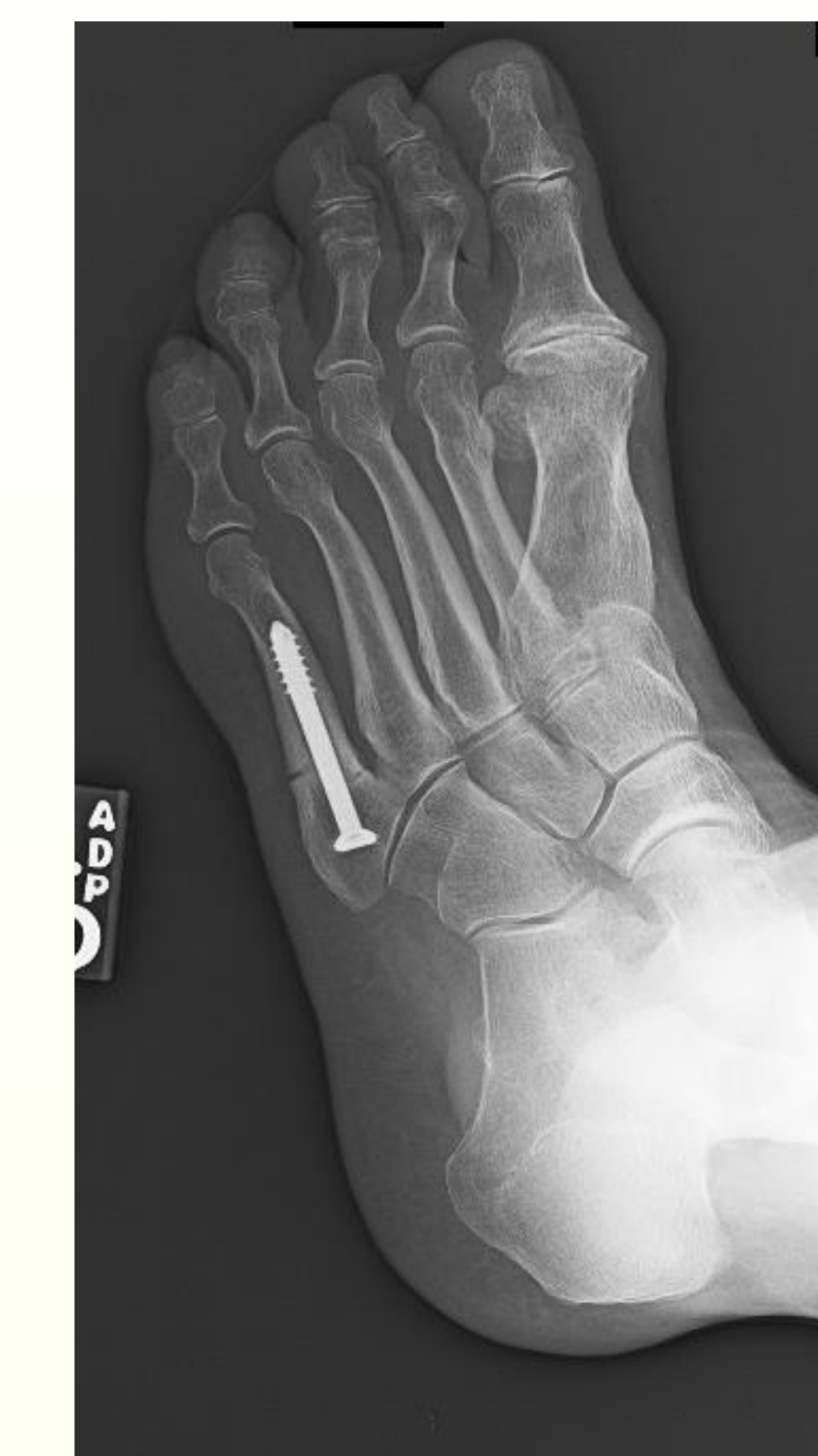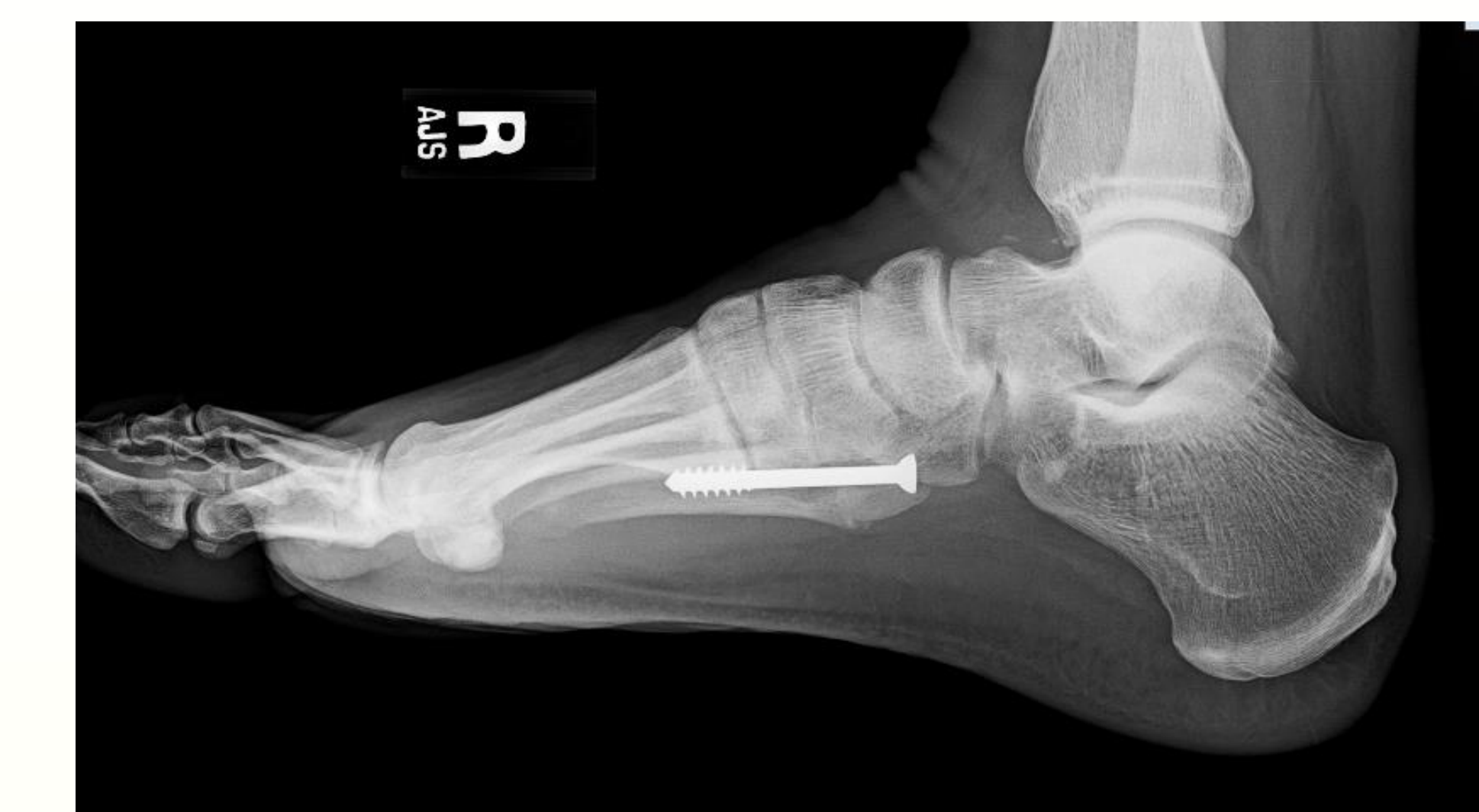EXAMPLES OF IM SCREWS VIOLATING THE METATARSAL-CUBOID JOINT



Example of an IM screw violating the joint. Also seen is resultant lucency in the cuboid from the screw head



Examples of IM Screws Not Involving the Metatarsal Cuboid joint



REFERENCES

1. Fleischer et al (2017) Forefoot Adduction is a Risk Factor for Jones Fracture. JFAS 2017 56 (5)
2. Porter, David A, et al. Fifth Metatarsal Jones Fracture Fixation With a 4.5-mm Cannulated Stainless Steel Screw in the Competitive and Recreational Athlete: A Clinical and Radiographic Evaluation. Am J Sports Med. 2005;33:726-733
3. Den Hartog (2009). Fracture of the Proximal Fifth Metatarsal. Journal of the American Academy of Orthopaedic Surgeons. 17.
4. Reese et al (2004). Cannulated screw fixation of Jones fractures: a clinical and biomechanical study. American Journal of Sports Medicine. October-November:32(7)
5. DeSandis et al (2016). Multiplanar CT Analysis of Fifth Metatarsal Morphology: Implications for Operative Management of Zone II Fractures. Foot and Ankle International. May: 37(5).