

## Statement of Purpose

Angiosarcomas are malignant soft tissue tumors of vascular or lymphatic endothelial cell origin which account for less than 0.02% of all malignancies<sup>1-3</sup>. While these tumors may arise in various locations throughout the body, they most commonly present as a cutaneous subtype on the head and neck of elderly, white men<sup>1,2</sup>. Literature describing cutaneous angiosarcomas in the lower extremity is scarce. We present a case study of a patient diagnosed with cutaneous angiosarcoma of the foot and a review of the current literature.

## Literature Review

Angiosarcomas typically arise de novo; however, these tumors may occur after radiation therapy or in patients with chronic lymphedema<sup>3</sup>. Initially, cutaneous angiosarcomas may resemble a bruise or appear as multifocal, erythematous papules<sup>1</sup>. These may easily be mistaken for benign lesions leading to delayed diagnosis. A nodular component often develops as the tumor progresses and long standing lesions may ulcerate with associated hemorrhage<sup>1,2</sup>. While angiosarcomas are locally invasive, they also have a high propensity to spread hematogenously<sup>1</sup>. The lung is the most common site for metastases, followed by the liver, heart, bone and lymph nodes<sup>1</sup>.

Assessment begins with a biopsy to establish a definitive diagnosis. Histologically, the hallmark of angiosarcomas are abnormal, pleomorphic endothelial cells forming irregular vascular spaces<sup>1</sup>. Advanced imaging is used for staging and surgical planning. Magnetic resonance imaging (MRI) is used to define the extent of the primary tumor<sup>2</sup>. To evaluate for metastasis, the National Comprehensive Cancer Network recommends a chest and abdominal/pelvic computed tomography (CT) in addition to central nervous system imaging<sup>4</sup>.

Treatment options are dictated by the size of the primary tumor and the presence or absence of distant metastasis<sup>1</sup>. Complete surgical excision with 2 centimeter (cm) clear margins is the optimal treatment<sup>4</sup>. Amputation is reserved for patients that would be left with a nonfunctional limb. Adjunctive radiotherapy to the primary site and regional lymph nodes has shown to reduce mortality<sup>5</sup>. Chemotherapy is typically indicated for metastatic angiosarcoma or in palliative cases<sup>2</sup>. Isolated limb perfusion with tumor necrosis factor  $\alpha$  (TNF- $\alpha$ ) has shown promise in recent studies, though further evidence is needed before this becomes a viable treatment option.<sup>3</sup>

Prognosis is generally poor due to a high recurrence rate (26-86%) and early metastasis<sup>3,5,6</sup>. The reported five-year survival rate ranges from 12-35%<sup>5</sup>. Even with localized disease, it is estimated only 60% survive past five years<sup>7</sup>. Although prognostic factors remain unclear, tumors measuring >5 cm and those with high mitotic counts are associated with poorer outcomes<sup>7,8</sup>.

## Case Study

An 81 year-old-man with a past medical history of Parkinson's disease with Lewy Body Dementia and Diabetes Mellitus, presented with a soft tissue mass on the lateral aspect of his left foot. The lesion was firm, mobile, flesh colored and pedunculated (Figure 1A). With an initial diagnosis of a benign fibroma, the patient was treated conservatively. The following year the mass had progressed and the patient was re-evaluated. The lesion had increased in size, altered color, changed texture, and would periodically ulcerate (Figure 1B,C). A punch biopsy was performed and sent for pathological analysis, revealing cutaneous angiosarcoma. Microscopically, an infiltrative pattern of abnormal,

pleomorphic cells forming irregular vascular spaces was appreciated via CD31 immunostaining and hematoxylin-eosin (H&E) staining (Figure 2). The patient was promptly referred to the General Surgery Department for further management with the recommendations to obtain the following: an MRI of his foot for primary tumor analysis; a chest and abdomen/pelvis CT; and a head MRI to determine extent of metastasis. The patient declined radiation and chemotherapy treatments, desiring only local surgical excision of the mass with skin graft or flap closure. Due to the patient's comorbidities and declining health, he died prior to advanced imaging and surgical intervention.

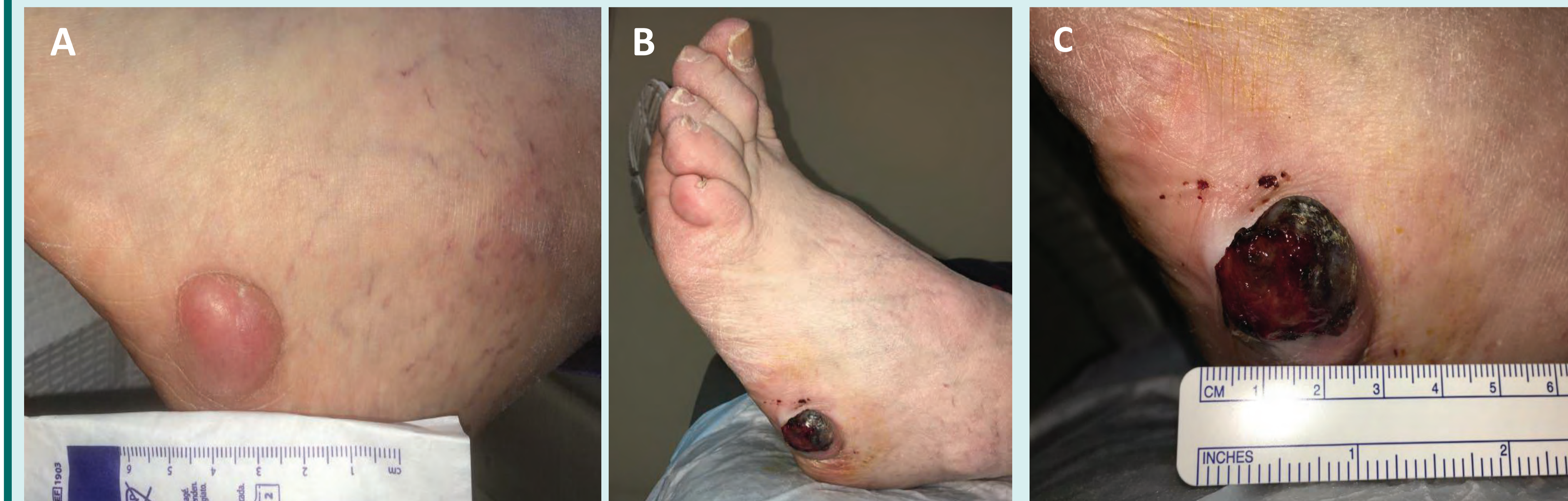

Figure 1. Clinical images documenting the evolution of an angiosarcoma of the left foot. Initial presentation (A), clinical appearance at one year (B,C).

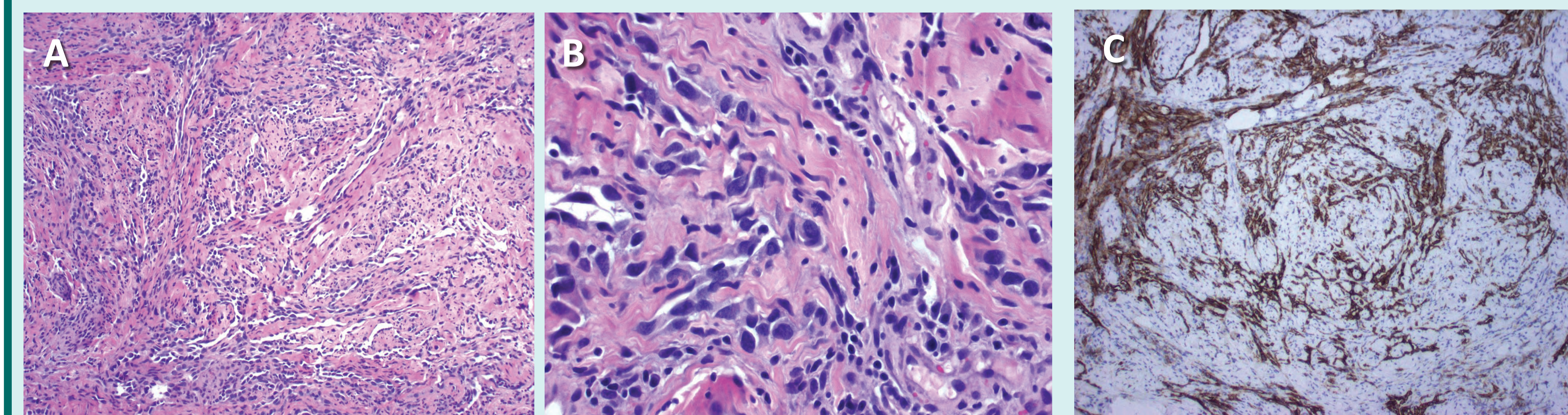


Figure 2. Haematoxylin-eosin stained sections of an angiosarcoma (A; magnification 10x, B; magnification 40x). CD31 immunostaining (C; magnification 20x) demonstrating infiltrative pattern of abnormal, pleomorphic cells forming irregular vascular spaces.

## Analysis & Discussion

Angiosarcoma is a rare and aggressive soft tissue malignancy of vascular or lymphatic endothelial cell origin<sup>1</sup>. Cutaneous angiosarcoma is a common subtype with variable presentations. These may be mistaken for benign lesions, leading to delayed diagnosis, thereby worsening prognosis. The optimal treatment is gross resection of the tumor with negative margins followed by wide-field radiotherapy<sup>1,2,4</sup>. The role of adjunctive chemotherapy remains investigational; however, it is recommended in metastatic disease and palliative cases<sup>1,2</sup>.

Angiosarcomas rarely occur in the lower extremity, although there have been case reports which describe these tumors arising from the femoral artery or within the bones of the foot<sup>9,10</sup>. To our knowledge, there is only one other case report of cutaneous angiosarcoma presenting in the foot. Tenjarla et al. described a case of a 90 year-old man with an ulcerative cutaneous angiosarcoma of the foot in the setting of chronic lymphedema<sup>5</sup>. The patient declined surgical intervention and was treated with radiation therapy. After one month of treatment, the authors reported excellent subjective and objective results with almost complete resolution of the cutaneous ulcerations. In our case study, due to other comorbidities and declining health, the patient died prior to surgical intervention or adjunctive therapies.

In conclusion, we present a rare case of cutaneous angiosarcoma of the foot as well as a current literature review. It is important to biopsy suspicious lesions and place timely referrals for appropriate management. The goal of this case study is to bring awareness to this potentially life-threatening condition while emphasizing a multidisciplinary approach to treatment.

## References

- Young R, Brown N, Reed M, et al. Angiosarcoma. *Lancet Oncol* 11: 983-991, 2010.
- Mendenhall W, Mendenhall C, Werning J, et al. Cutaneous angiosarcoma. *Am J Clin Oncol* 29:524-528, 2006.
- Huis E, Grünhagen D, Verhoef C, et al. Isolated limb perfusion for locally advanced angiosarcoma in extremities: a multi-centre study. *Eur J Cancer* 85:114-121, 2017.
- Demetri G, Baker L, Benjamin R, et al. Soft tissue sarcoma NCCN clinical practice guidelines in oncology. *J Natl Compr Cancer Netw* 8:630-674, 2010.
- Tenjarla S, Sheils L, Kwiatkowski T, et al. Cutaneous angiosarcoma of the foot: a case report and review of the literature. *Case Rep Oncol Med* 1-5, 2014.
- Maddox J, Evans H. Angiosarcoma of skin and soft tissue: study of forty four cases. *Cancer* 48:1907-1921, 1981.
- Abraham J, Hornicek F, et al. Treatment and outcome of 82 patients with angiosarcoma. *Ann Surg Oncol* 14:1953-1967, 2007.
- Lahat G, Dhuka A, et al. Outcome of locally recurrent and metastatic angiosarcoma. *Ann Surg Oncol* 16:2502-2559, 2009.
- Balaji G, Arockiaraj J, et al. Primary epithelioid angiosarcoma of the calcaneum a diagnostic dilemma. *J Foot Ankle Surg* 53:239-242, 2014.
- Choi S, Min S, et al. Intimal angiosarcoma presenting with common femoral artery aneurysm. *J of Vasc Surg*. 56:819-821, 2012.
- Hart H, Mandavilli S. Epithelioid angiosarcoma a brief diagnostic review and differential diagnosis. *Arch Pathol Lab Med* 135: 268-272, 2011.