



# Tensile Strength of the Medial Collateral Ligament of the Hallux

Kevin Rabie DPM PGY-2, EVMS Podiatric Surgery Residency  
Patrick Agnew DPM, EVMS Residency Director

## Introduction

Hallux valgus is a foot disorder characterized by lateral deviation of the first metatarsophalangeal joint, and medial deviation of the first metatarsal. The precise etiology leading to the development of hallux valgus deformity remains unclear and may be multifactorial. One of the most notable causes can be due to failure of the soft tissues at the first metatarsophalangeal joint as the deformity has been observed to increase after surgical release of the the medial collateral ligament (MCL) or after acute rupture of this ligament. The MCL of the hallux is essential for maintaining biomechanical functional alignment and position of the hallux at the joint. Thus failure of this tissue structure, whether through attenuation, trauma, or surgical release, is associated with hallux valgus.

There has been no uniform technique for the repair or of the MCL described in previous literature, however a novel approach uses a bone anchors and non absorbable high strength suture to recreate the ligament. Bone anchors are inserted in the medial head of the metatarsal and the medial base of the proximal phalanx (as seen in Illustration 1) and cinched closer together with the suture. The pullout force of the anchors and mechanical strength of the Force Fiber suture are well documented, but the tensile strength of the the native MCL has never been studied.

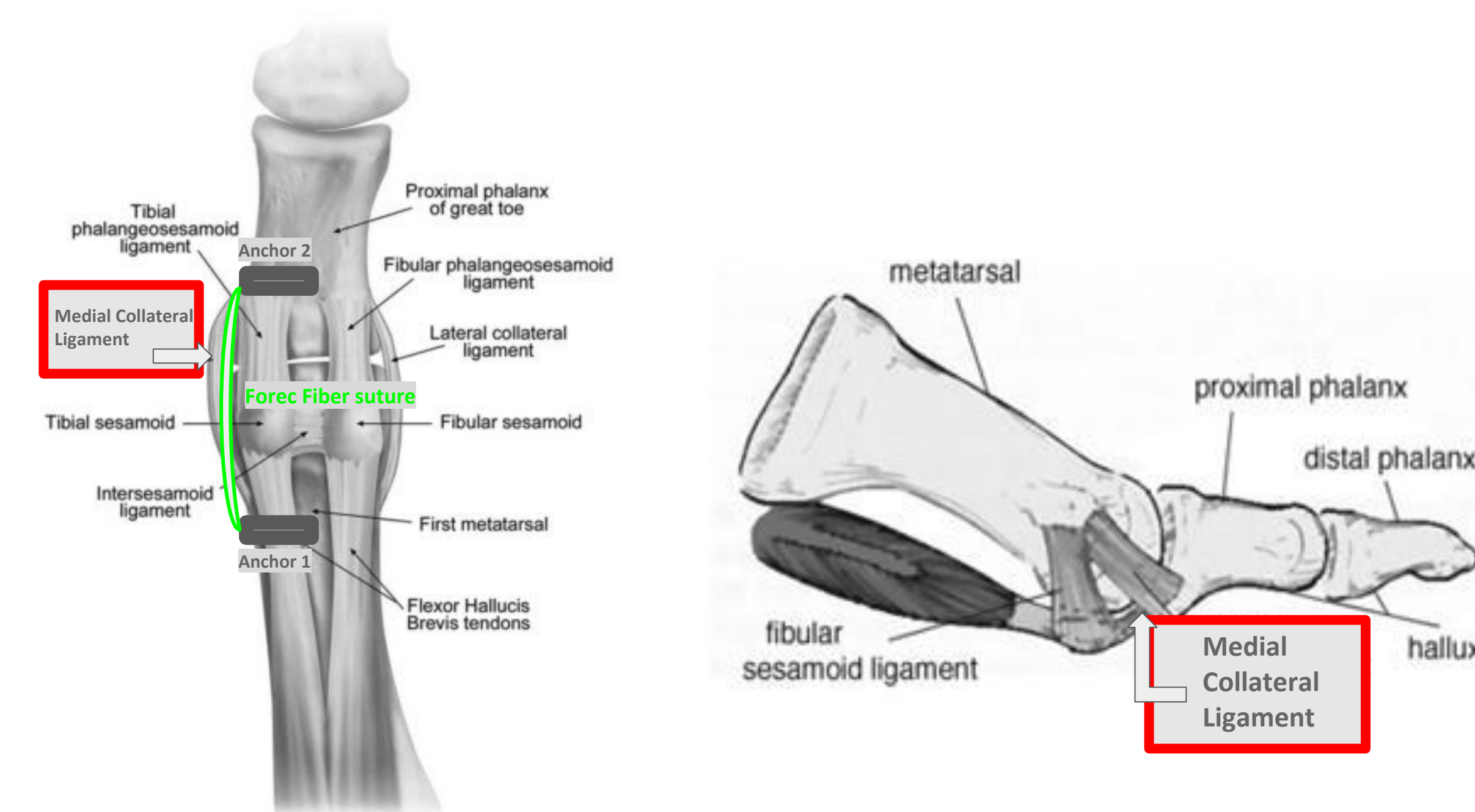


Illustration 1: The location of the both the native MCL of the hallux, and the placement of bone anchors and high strength suture for recreation of the ligament

## Objectives

Augmenting or replacing this structure utilizing suture material attached to bone anchors on either side of the first MPJ can enhance correction of hallux valgus with immediate intraoperative results. However, testing and quantification of this ligament's tensile strength are necessary to understand the innate anatomic qualities that must be replicated by any artificial replacement construct. This value is what we believe to be the necessary strength that must be matched or exceeded.

## Materials and Methods

A total of three different cadaveric specimens were made available for use from the Stryker mobile lab. Dissection of the three specimens was then accomplished at the metatarsophalangeal joint. This included sectioning all soft tissue elements leaving the MCL as the only attachment between the head of the first metatarsal and the base of the first proximal phalanx. The in situ testing on the models involved axial tensile loading, with peak load at the failure point of the ligament being documented upon failure.

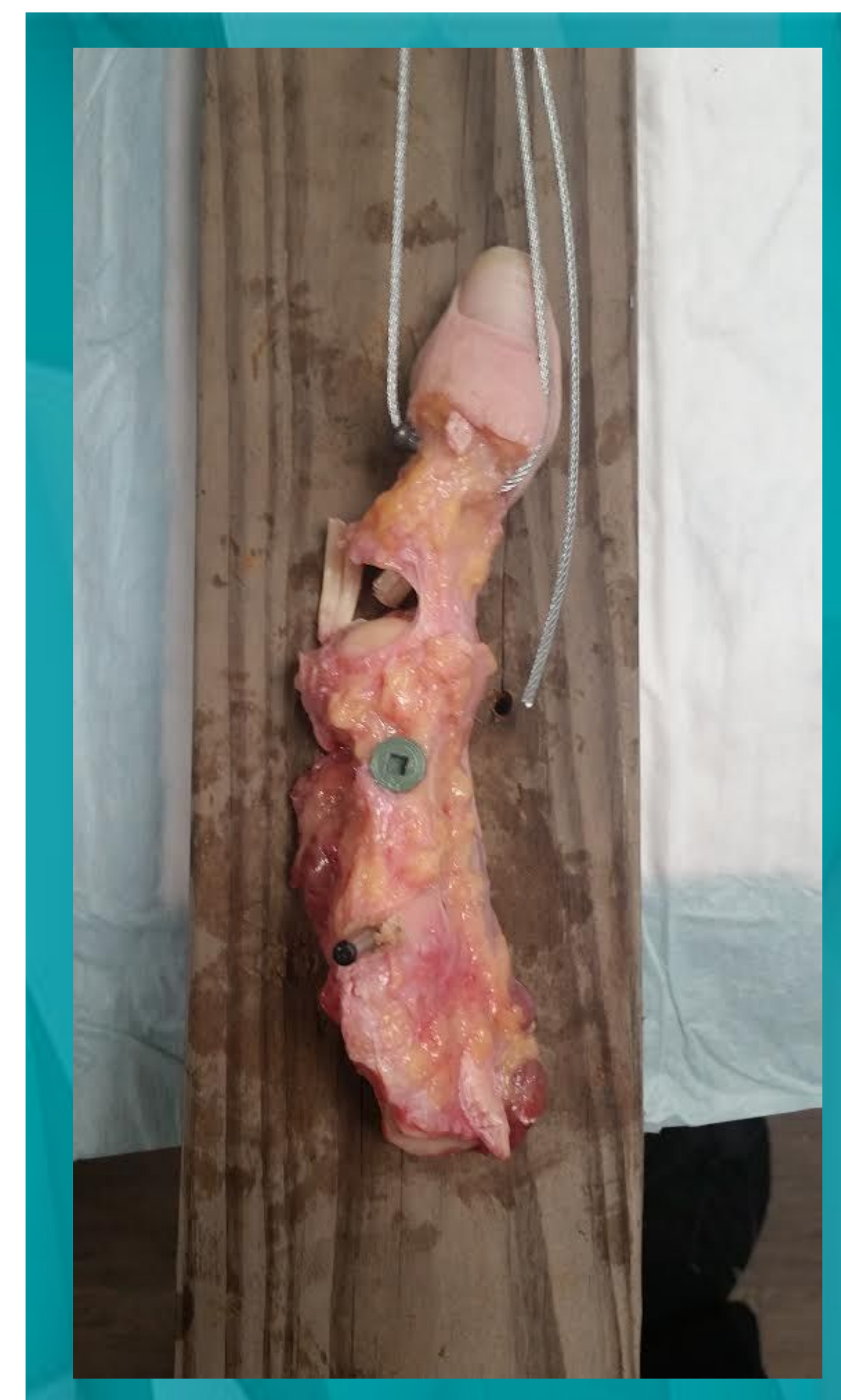


Figure 1: The first ray removed from the cadaveric specimen, anchored into place, with unnecessary soft tissue attachments dissected away

### Loading Protocol:

Once securely fastened to the gauge and anchored in place, pull was applied to the handle of the gauge until mechanical failure of the the MCL. Peak pressure was recorded by the gauge and documented.

### Attachment Method:

The first ray was anchored in place with screws through the metatarsal to the surface used as the base. A hole was drilled through the head of the proximal phalanx in a medial to lateral direction and braided steel wire was guided through and attached to a carabiner. The carabiner was fastened to the lever of a mechanical force gauge.

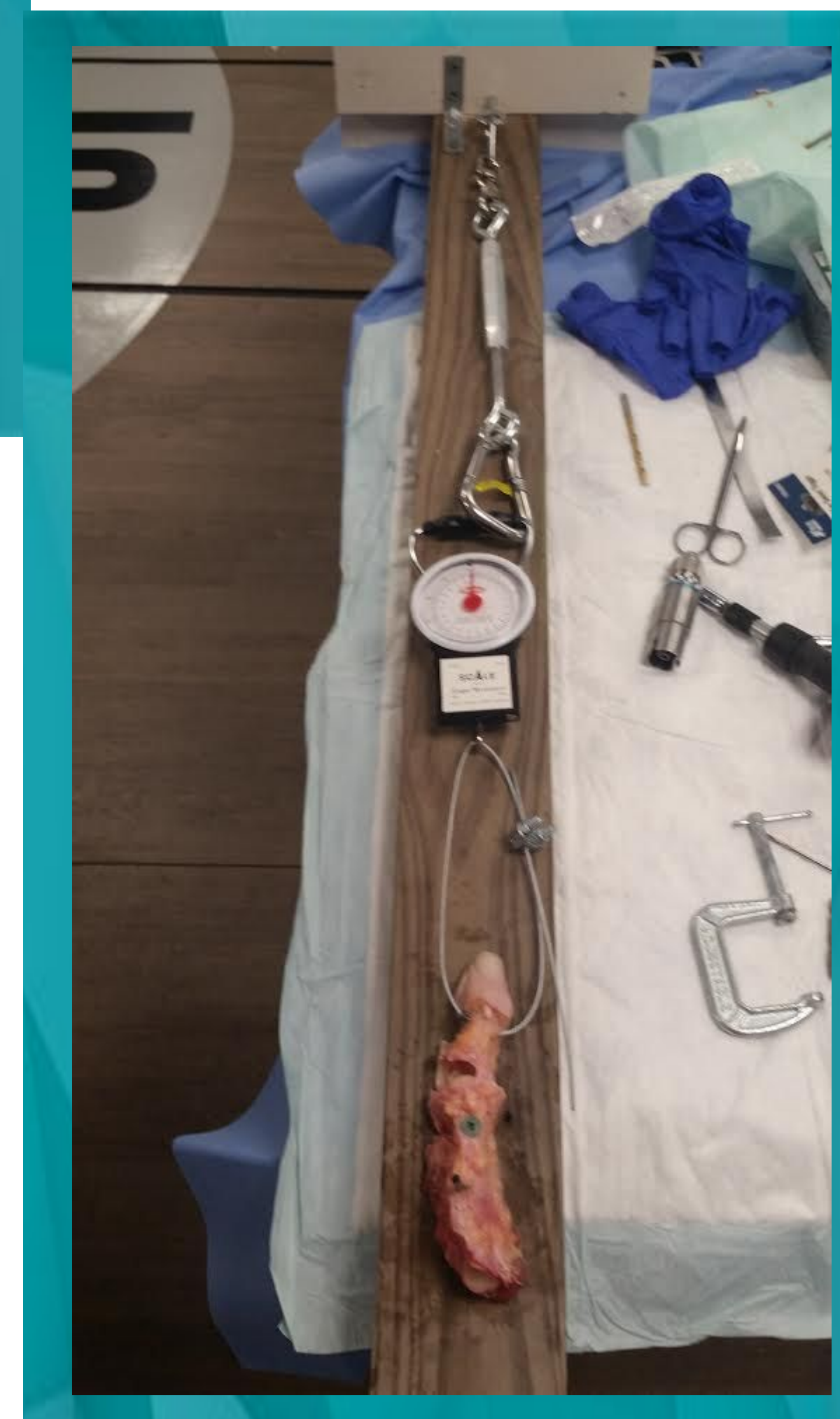


Figure 2: The custom testing jig in full

## Results

The MCL was found to fail at 50lbs (22.7kg) of axial force in specimen one, 42lbs (19.1kg) in specimen 2, and 52lbs (23.6kg) in specimen 3. This would represent the peak strength of the ligament along its longitudinal axis.

## Discussion

These measurements provide new baseline data for the design and selection of a MCL replacement in order to reproduce normal hallux kinematics. The choice of bone anchors and connecting suture material must match or exceed this value for proper anatomical repair to be accomplished. While the number of specimens was fairly limited in this study, having a general target value to exceed with any artificial construct aids in the fine tuning of this type of procedure. By augmenting this structure in hallux valgus procedures, increased correction can be attained with a lower likelihood of recurrence of deformity.

## References

1. Coughlin MJ. Hallux valgus: J Bone Joint Surg [Am] 1996;78-A:932-66.
2. Sander AP, Snijders CJ, Bert VL. Medial deviation of the first metatarsal head as a result of flexion forces in hallux valgus. Foot Ankle Int. 1992;13:515-22.
3. Hideji K, Zong-ping L, Harold B, Kai-Nan A. Role of medial capsule and transverse metatarsal ligament in hallux valgus deformity. Clinical orthopaedics and related research. 1998;354:235-40
4. Bock P, Kristen KH, Kroner A, Engel A. Hallux valgus and cartilage degeneration in the first metatarsophalangeal joint. J Bone Joint Surg Br. 2004;86:669-73.
5. Kadakia AR, Molloy A. Current concepts review: traumatic disorders of the first metatarsophalangeal joint and sesamoid complex. Foot Ankle Int. 2011 Aug;32(8):834-9
6. Fabek LG, Zekhnini C, Farrokh D, Descamps PY, Delincé PE. Traumatic hallux valgus following rupture of the medial collateral ligament of the first metatarsophalangeal joint: a case report. J Foot Ankle Surg. 2002 Mar-Apr;41(2):125-8.
7. Douglas DP, Davidson DM, Robinson JE, Bedi DG. Rupture of the medial collateral ligament of the first metatarsophalangeal joint in a professional soccer player. J Foot Ankle Surg. 1997 Sep-Oct;36(5):388-90.
8. Bohay DR, Johnson KD, Manoli A. The traumatic bunion. Foot Ankle Int. (2) 1996 Jul;17(7):383-7.
9. Kura H, Luo ZP, Kitaoka HB, An KN. Role of medial capsule and transverse metatarsal ligament in hallux valgus deformity. Clin Orthop Relat Res. 1998 Sep;354:235-40.
10. Wen JM, Tong Y, Han FY, Sun YS, Sun WD, Sang ZC, Hu HW, Lin XX, Wu XB, Liang Z. Observation on pathological changes of the medial aspect of the first metatarsal head of hallux valgus. Zhongguo Gu Shang. 2008 Dec;21(12):883-5.
11. Choi SJ, Kim BC, Eun IS, Huh JW. Consideration of various medial capsulorrhaphy methods in hallux valgus surgery. J Korean Foot Ankle Soc. 2008 Jun;12(1):9-13.

Kevin Rabie DPM, PGY-2

• Email: kevin.rabie@gmail.com

Dr. Patrick Agnew DPM, Residency Director EVMS

• Email: pagnw@aol.com