

Case Report: Tarsal Tunnel Syndrome Secondary to a Schwannoma in a Patient with Myotonic Dystrophy

Randal Lepow, DPM, PGY2; R. Scott Dominguez, DPM, PGY2; Sunil K. Jeganathan, MD, DPM, PGY2; Kirubel T. Gebresenbet, DPM, PGY2

St. Joseph Medical Center, Houston, Texas

INTRODUCTION:

Tarsal tunnel syndrome is encountered frequently in nearly all foot and ankle practices. We describe a schwannoma in a patient with myotonic dystrophy that mimicked the symptoms of tarsal tunnel syndrome. Schwannomas are tumors of the nerve sheath and have a tendency to present only when it compresses surrounding tissues and thus causes associated symptoms due to a mass effect. The schwannoma itself is not usually symptomatic.

METHODOLOGY:

Case report on a patient with a history of myotonic dystrophy. Patient was followed for 1 year after surgical excision of the schwannoma.

ETIOLOGY:

The etiology of schwannoma is unknown. However, they are associated with genetic diseases such as Neurofibromatosis Type I (von Recklinghausen disease) and Type II Schwannomatosis. In these cases, multiple schwannomas are usually seen.

Myotonic Dystrophy (DM) represents a group of autosomal dominant, multisystemic diseases (ex: respiratory insufficiency, cardiac conduction defects, insulin resistance) that share the clinical features of myotonia, muscle weakness, and early-onset cataracts. DM is the most common adult muscular dystrophy. There are multiple reports of tumors in individuals with DM (cont.)

ETIOLOGY: (cont.)

The increased trinucleotide repeat expansion in DM suggest that genetic instability can predispose them to tumor development. The most common tumor type in patients with DM is pilomatricomas (benign calcifying cutaneous tumor derived from hair matrix cells).

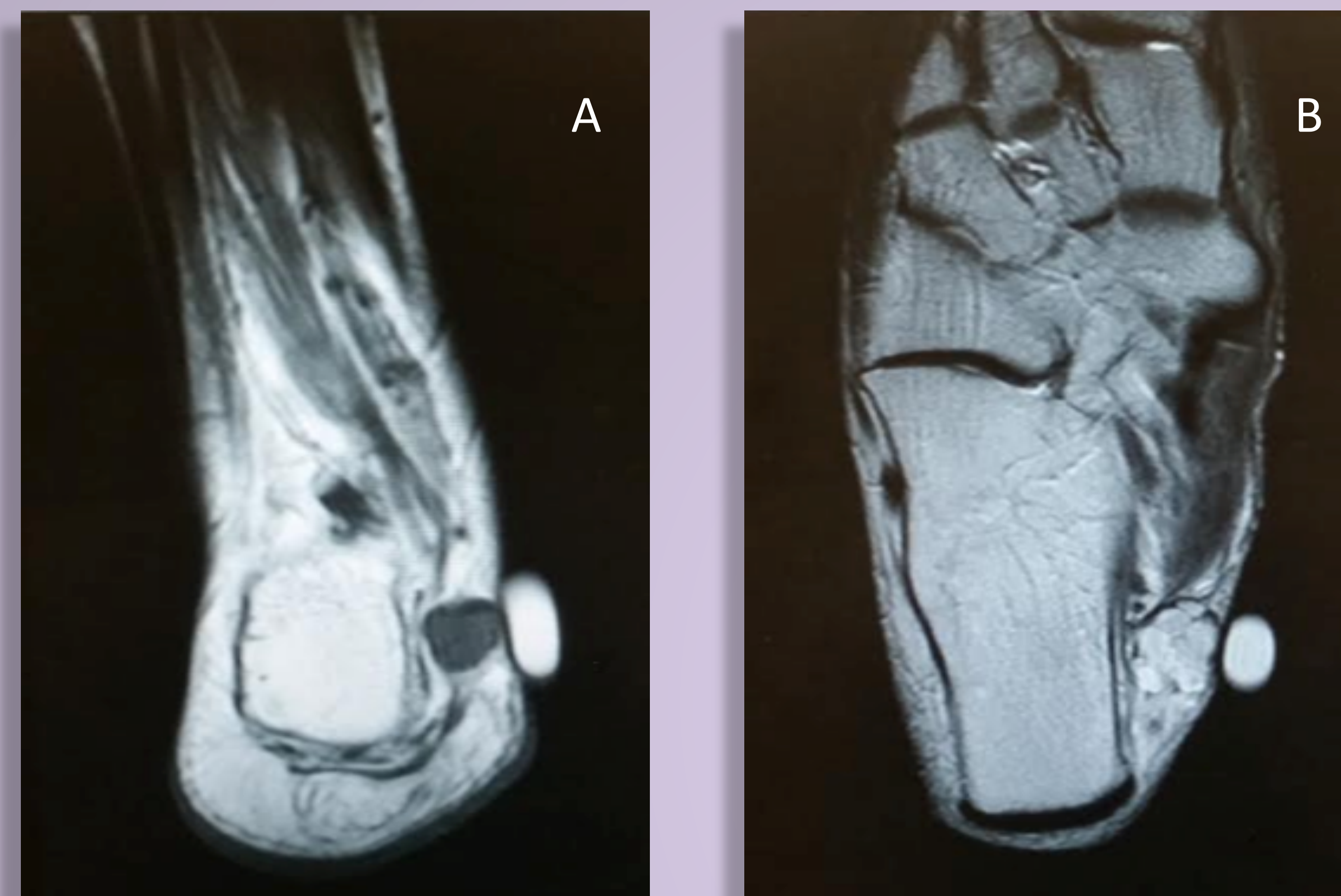

Figure (A) T1 weighted coronal MR image of schwannoma invested posterior tibial tendon. Figure (B) shows a T1 weighted axial MR image of the schwannoma.

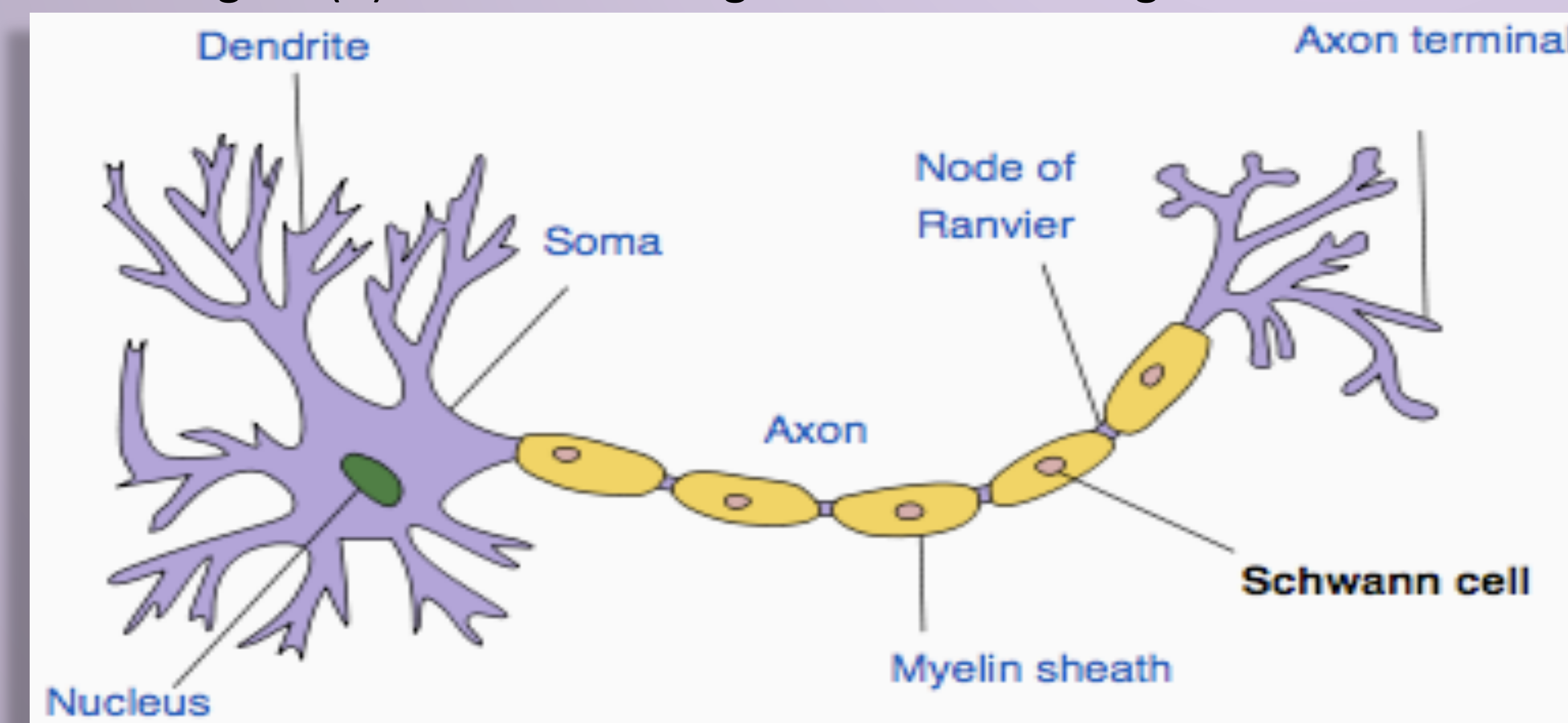
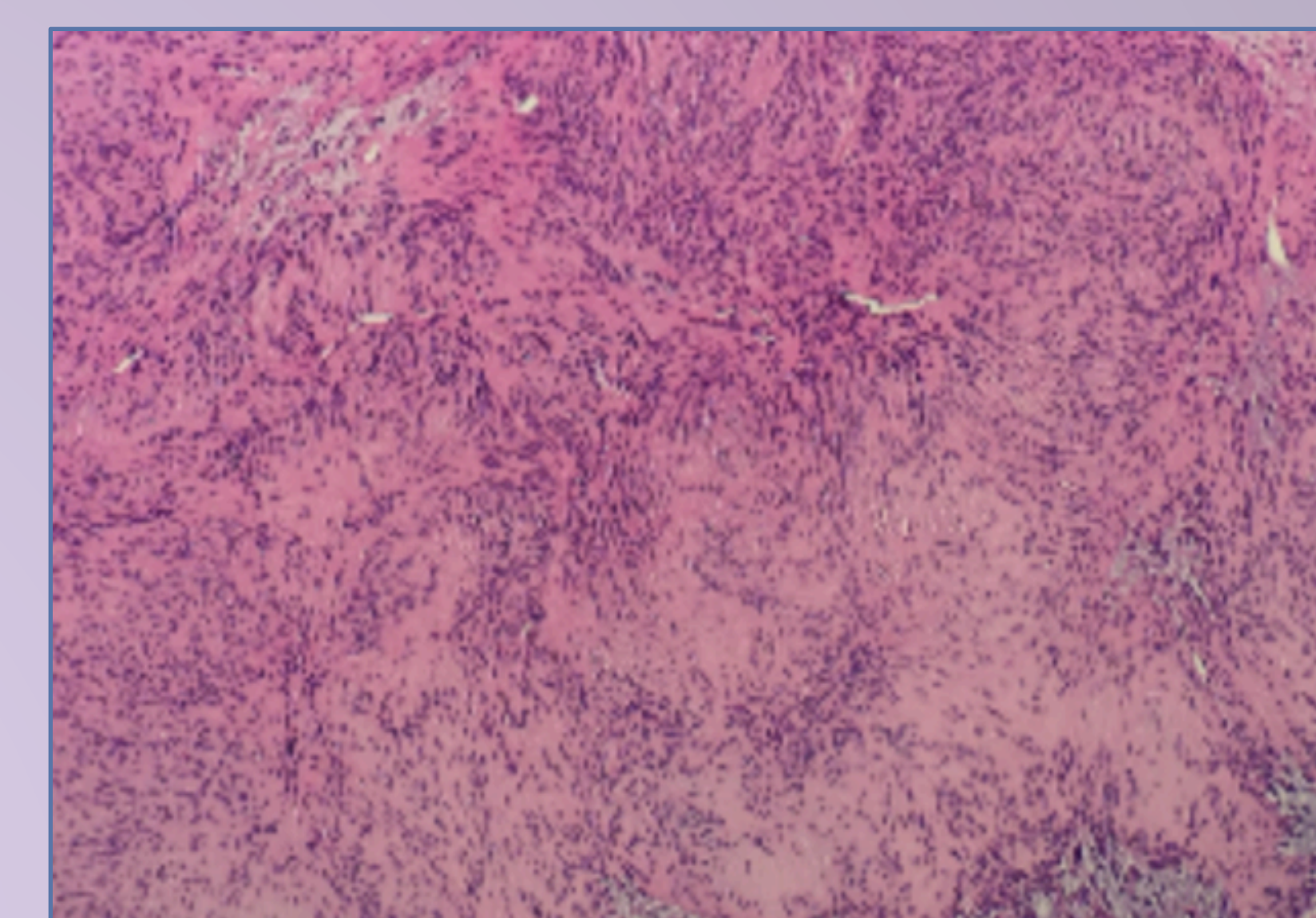
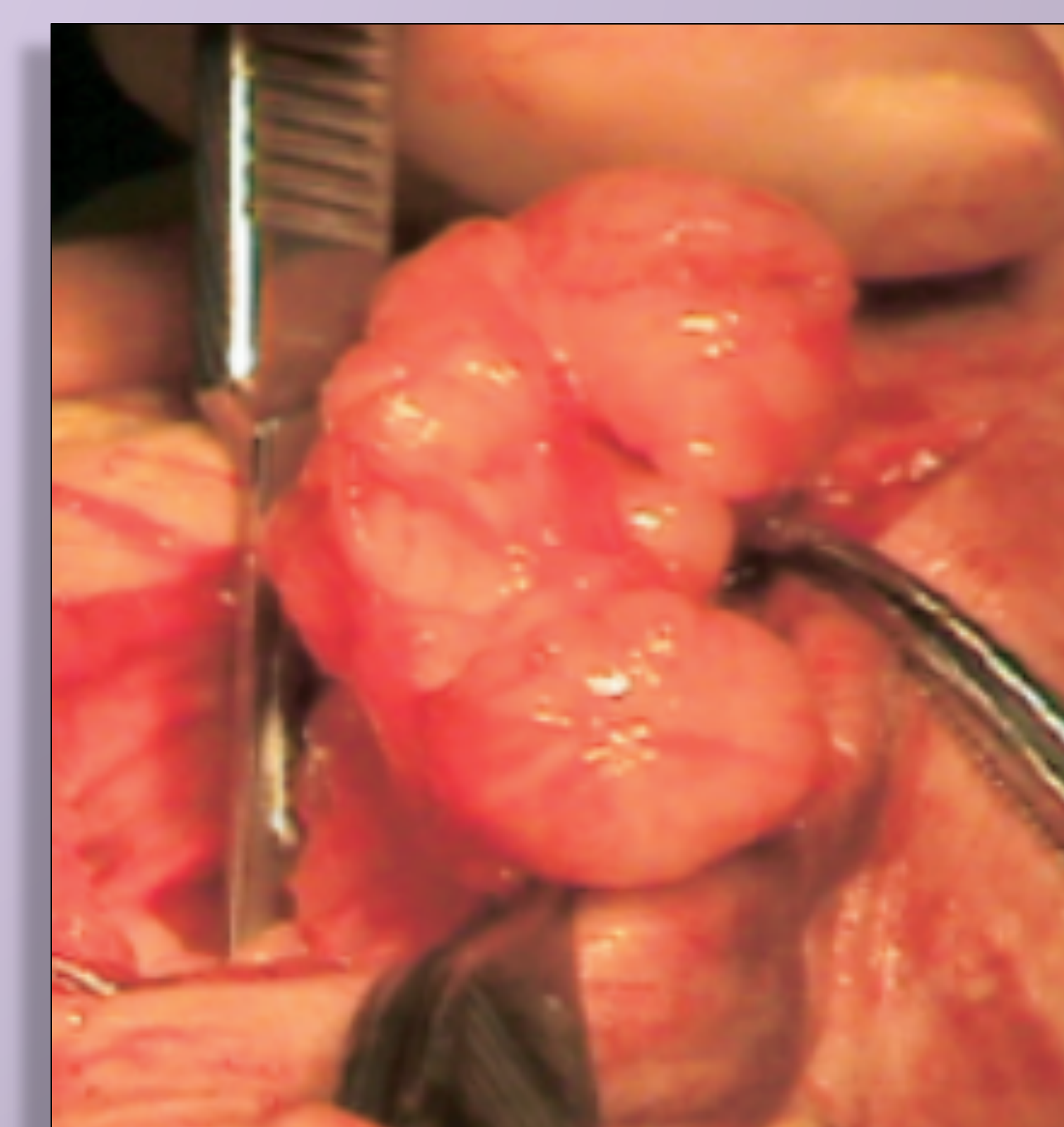


Illustration of Nerve Cell.



Microscopy of schwannoma showing focal palisading nuclei surrounding pink area (Verocay Bodies).



Gross image of the schwannoma next to the posterior tibial tendon.

REFERENCES:

- Carter, J., Ben-Ghashir, N., & Chandrasekar, C. R. (2016). Giant schwannoma of the medial plantar nerve. *The Foot*, 26, 4-6.
- Das et al. (2012). Correlates of Tumor development in patient with myotonic dystrophy. *J Neurol*, 259(10) 2161-2166.
- Joshi, R. (2012). Learning from eponyms: Jose Verocay and Verocay bodies, Antoni A and B areas, Nils Antoni and Schwannomas. *Indian Dermatology Online Journal*, 3(3), 215-219.
- Kallini, J. R., & Khachemoune, A. (2014). Schwannoma of the left foot: a brief overview with focus on associated clinical syndromes. *Journal of the American Podiatric Medical Association*, 104(5), 535-538.
- Ikushima, K., Ueda, T., Kudawara, I., Nakanishi, K., & Yoshikawa, H. (1999). Plexiform schwannoma of the foot. *European radiology*, 9(8), 1653-1655.
- Mangrulkar, V. H., Brunetti, V. A., Gould, E. S., & Howell, N. (2007). Unusually large pedal schwannoma. *The Journal of Foot and Ankle Surgery*, 46(5), 398-402.
- Mueller, C. M., Hilbert, J. E., Martens, W., Thornton, C. A., Moxley, R. T., & Greene, M. H. (2009). Hypothesis: neoplasms in myotonic dystrophy. *Cancer Causes & Control*, 20(10).

PROCEDURE:

A curvilinear incision at the medial ankle was made. The schwannoma was carefully freed from surrounding tissues and excised. Surgical sites were irrigated and re-approximated.

PATHOLOGY REPORT:

- Multilobulated specimen with light tan straw yellow color
- Microscopic findings- dermal nodule with fusiform cells and focal palisading of nuclei; **Verocay bodies** present. No prominent hemorrhage or necrosis.

Final Diagnosis: Schwannoma

Note: Verocay body(VB) is diagnostic of a schwannoma. VB's are stacked arrangements of 2 rows of elongated palisading nuclei that alternate with acellular zones made up of cytoplasmic processes of the Schwann cells.

RESULTS:

Patient had complete resolution of symptoms immediately after the surgery. Over a 1 year period after surgery, patient remained symptom free. Patient was completely satisfied with his results.

DISCUSSION:

Studies suggest female DM patients are more likely to develop tumors. Schwannomas are frequently discussed in the literature, however its association with myotonic dystrophy has not been well understood and more research is required on the topic.