Mechanical Axis Method to Determine First Intermetatarsal Angle and Tibial Sesamoid Position

Noman A. Siddiqui, DPM, MHA,[1] Prianka Sharma, DPM,[2] Jessica Fink, DPM,[3] Alison D'Andelet, DPM, MHA,[2] Emily Chau, DPM,[3] and Guido LaPorta, DPM, MS[2,4]

[1]International Center for Limb Lengthening, Rubin Institute for Advanced Orthopedics, Sinai Hospital of Baltimore, Baltimore, Maryland, USA; [2]Our Lady of Lourdes Memorial Hospital, Binghamton, New York, USA; [3]Baltimore VA/Sinai Hospital Residency Program, Baltimore, Maryland, USA; [4]Geisinger Community Medical Center, Scranton, Pennsylvania, USA

For this radiographic review of normal feet, FDA approval was not applicable. None of the authors have any relevant conflicts of interest to report.

Purpose

- The anatomic axis of the metatarsals is routinely used to obtain the intermetatarsal angle (IMA) and tibial sesamoid position (TSP). However, the anatomic axis is disrupted in feet that have had osteotomies, surgery, posttraumatic conditions, or congenital deformities.
- The mechanical axis of the metatarsals has not been described in the literature.
- The goals of this study are to identify:
  - Normal mechanical axes of the first and second metatarsals
  - Normal values for the first metatarsal mechanical IMA (mIMA), first metatarsal anatomic IMA (aIMA), mechanical TSP (mTSP), and anatomic TSP (aTSP)
  - Normal values for the first metatarsal anatomic-mechanical angle (AMA) and the second metatarsal AMA
- First mIMA and mTSP will be compared to the first aIMA and aTSP to determine whether variance exists.

Methodology & Hypothesis

- The institutional review board approved this retrospective radiographic review of 50 normal feet (40 patients) without hallux valgus deformity (Table 1).
- We hypothesized that values obtained using the mechanical axis and those obtained using the anatomic axis would be similar.
- All measurements were obtained from weight bearing anteroposterior view radiographs.
- All angles were measured by two authors (PS and NAS) utilizing calibrated software (Merge Healthcare, eFilm Workstation 4.2.0, Chicago, IL).
- The first metatarsal aIMA is the angle formed by the anatomic axis (mid-diaphyseal line) of the first metatarsal and the anatomic axis of the second metatarsal (Fig. 1).
- To draw the mechanical axis of a metatarsal (Fig. 2A–B):
  - Draw a proximal joint line: connect the medial and lateral edges of the articular surfaces of the proximal metatarsal.
  - Draw a distal joint line: connect the medial and lateral edges of the articular surfaces of the distal metatarsal.
  - To draw the mechanical axis: Draw a line from the midpoint of the proximal joint line to the midpoint of the distal joint line.
- The first metatarsal mIMA is the angle formed by the mechanical axis of the first metatarsal and the mechanical axis of the second metatarsal (Fig. 2).
- The first metatarsal AMA is the angle formed between the anatomic and mechanical axes of the first metatarsal (Fig. 3).
- The second metatarsal AMA is the angle formed between the anatomic and mechanical axes of the second metatarsal (Fig. 3).
- TSP was measured using the anatomic and mechanical axes of the first metatarsal to determine the aTSP and mTSP, respectively (Fig. 4).

Table 1. Patient Demographics.

Age	Average: 45.6 years
Gender	8 men
	32 women
Self-reported race/ethnicity	14 Caucasian
	3 Asian
	23 African American
Laterality	26 left feet
	24 right feet

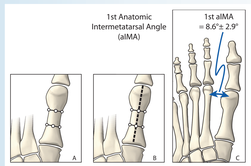

Figure 1. A and **B**, Panels show how to draw the anatomic axis (mid-diaphyseal line) of the first metatarsal. **C**, First metatarsal anatomic intermetatarsal angle (aIMA) is formed by the anatomic axis of the first metatarsal and the anatomic axis of the second metatarsal.

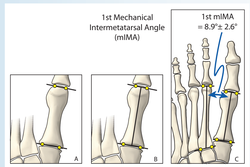

Figure 2. A and **B**, Panels show how to draw the mechanical axis of the first metatarsal. **C**, First metatarsal mechanical intermetatarsal angle (mIMA) is formed by the mechanical axis of the first metatarsal and the mechanical axis of the second metatarsal.

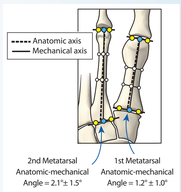

Figure 3. The first metatarsal anatomic-mechanical angle is the angular difference between the anatomic and mechanical axes of the first metatarsal. The second metatarsal anatomic-mechanical angle is the angular difference between the anatomic and mechanical axes of the second metatarsal.

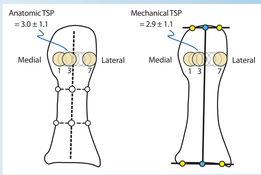

Figure 4. Hardy and Clapham[6] tibial sesamoid position classification based on the anatomic axis and the mechanical axis.

Literature Review

- Meyr et al.[1] evaluated 373 patients with normal first metatarsal angles. They found the mean IMA and TSP were 9.93° and 3.63, respectively.
- Dayton et al.[2] looked at pre- and postoperative angles of 25 feet with hallux valgus. They determined that the mean preoperative IMA and TSP were 14.9° and 5.6, respectively.
- LaPorta et al.[3] applied concepts described by Paley[4] to identify the mechanical axis of the entire medial column. LaPorta et al.[3] evaluated 200 radiographs: 100 normal feet and 100 pathological feet that had symptomatic hallux valgus deformity. Their study found the mean IMA for the deformity group to be 13.5 ± 2.8° for the anatomic axis and 11.58 ± 1° for the mechanical axis. LaPorta et al.[3] did not report values for TSP with respect to the mechanical or anatomic axis.
- The normal aIMA value has been reported to be 8.3 ± 2.0 degrees.[5]

Results

- Radiographs of 50 feet (26 left feet, 24 right feet) with no pedal pathology were evaluated for six measurements (Tables 1 and 2).
- Values obtained using the mechanical axis were similar to values obtained using the anatomic axis.
- We observed high reliability (range, 0.981–1.0) between the two observers for all measurements and had a large enough sample size that this observation was not due to chance ($p < 0.001$) (Table 2).

Table 2. Normal values, correlation coefficients, and p values for six radiographic values of the first and second metatarsal that were obtained using the anatomic axis and the mechanical axis.

Measurements	Mean ± Standard Deviation	Correlation Coefficient	P values
First metatarsal aIMA	8.6° ± 2.9°	0.996	P <.001
First metatarsal mIMA	8.9° ± 2.6°	0.981	P <.001
First metatarsal AMA	1.2° ± 1.0°	0.991	P <.001
Second metatarsal AMA	2.1° ± 1.5°	0.996	P <.001
aTSP	3.0 ± 1.1	1.0	P <.001
mTSP	2.9 ± 1.1	1.0	P <.001

aIMA, anatomic intermetatarsal angle; AMA, anatomic-mechanical angle; aTSP, anatomic tibial sesamoid position; mIMA, mechanical intermetatarsal angle; mTSP, mechanical tibial sesamoid position.

Analysis & Discussion

- First metatarsal IMA and TSP are important measurements for radiographic evaluation for hallux valgus. Variability exists in how the first metatarsal IMA and TSP are measured.
- Our findings were consistent with other published data.[1,4]
- Minimal difference was found between the mechanical and anatomic IMAs, which were 8.9° ± 2.6° and 8.6° ± 2.9°, respectively (Table 2).
- Minimal difference was observed in TSP that was measured based on the mechanical and anatomic axes (2.9 ± 1.1 versus 3.0 ± 1.1).
- Only normal feet were included in our study, which made it easier to determine the anatomic axis lines.
- Posttraumatic deformities, prior osteotomies, previous surgery, or congenital deformities can make it difficult to define the anatomic axis of the metatarsal, which could introduce error when obtaining aIMA and aTSP (Fig. 5).
- Using the mechanical axis for IMA and TSP measurements will avoid errors that can be introduced when using the anatomic axis to obtain measurements of feet with osteotomies, previous surgery, posttraumatic conditions, or congenital deformities (Fig. 5).
- Since minimal differences exist between anatomic and mechanical IMA and TSP in normal feet, only the mechanical axis should be used to obtain mIMA and mTSP for all preoperative and postoperative measurements of feet with hallux valgus.

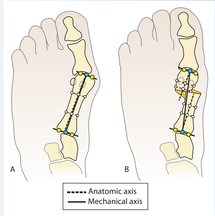

Figure 5. A, Before surgery for hallux valgus, the anatomic axis is relatively easy to identify and mostly overlaps the mechanical axis. **B**, After an osteotomy and realignment of the first metatarsal, the anatomic axis is disrupted and difficult to identify. This can introduce error when obtaining aIMA and aTSP. However, the mechanical axis is still able to be drawn, allowing mIMA and mTSP to be obtained.

References

1. Meyr AJ, Myers A, Pontious J. Descriptive quantitative analysis of hallux abductovalgus transverse plane radiographic parameters. *J Foot Ankle Surg.* 53(4):397–404, 2014.
2. Dayton P, Feilmeier M, Kauwe M, Hirschi J. Relationship of frontal plane rotation of first metatarsal to proximal articular set angle and hallux alignment in patients undergoing tarsometatarsal arthrodesis for hallux abducto valgus: a case series and critical review of the literature. *J Foot Ankle Surg.* 52(3):348–54, 2013.
3. S LaPorta GA, Nasser EM, Mulhern JL, Malay DS. The mechanical axis of the first ray: a radiographic assessment in hallux abducto valgus evaluation. *J Foot Ankle Surg.* 55(1):28–34, 2016.
4. Paley D. *Principles of Deformity Correction.* Springer: Berlin, Germany, 2005.
5. Lamm BM, Stasko PA, Gesheff MG, Bhave A. Normal foot and ankle radiographic angles, measurements, and reference points. *J Foot Ankle Surg.* 55(5):991–8, 2016.
6. Hardy RH, Clapham JC. Observations on hallux valgus; based on a controlled series. *J Bone Joint Surg Br.* 33-B(3):376–91, 1951.