

Utilization of Omega 3 Fish Skin Graft In The Case of Surgical Dehiscence of A 1st MPJ Arthrodesis with Associated Osteomyelitis

Gurleen K. Cheema DPM, Jonathan L. Hook, DPM, MHA
Mercy Hospital and Medical Center Chicago, Illinois

STATEMENT OF PURPOSE

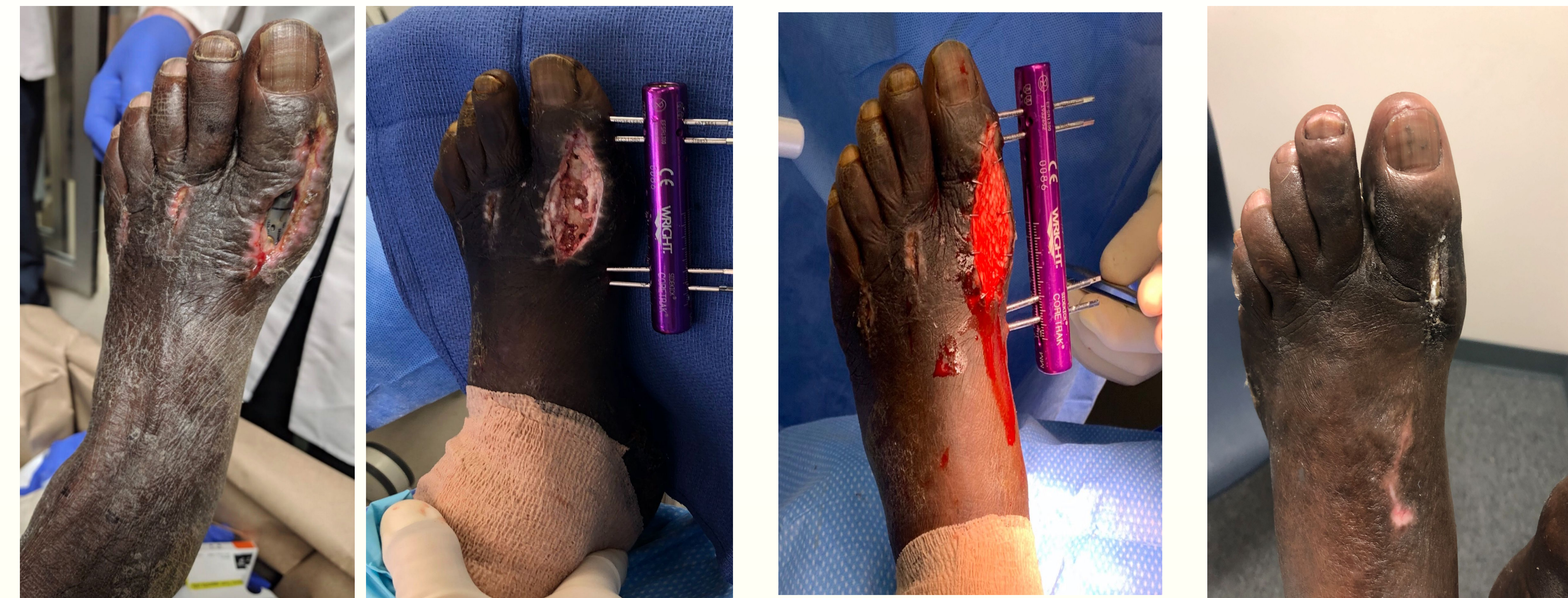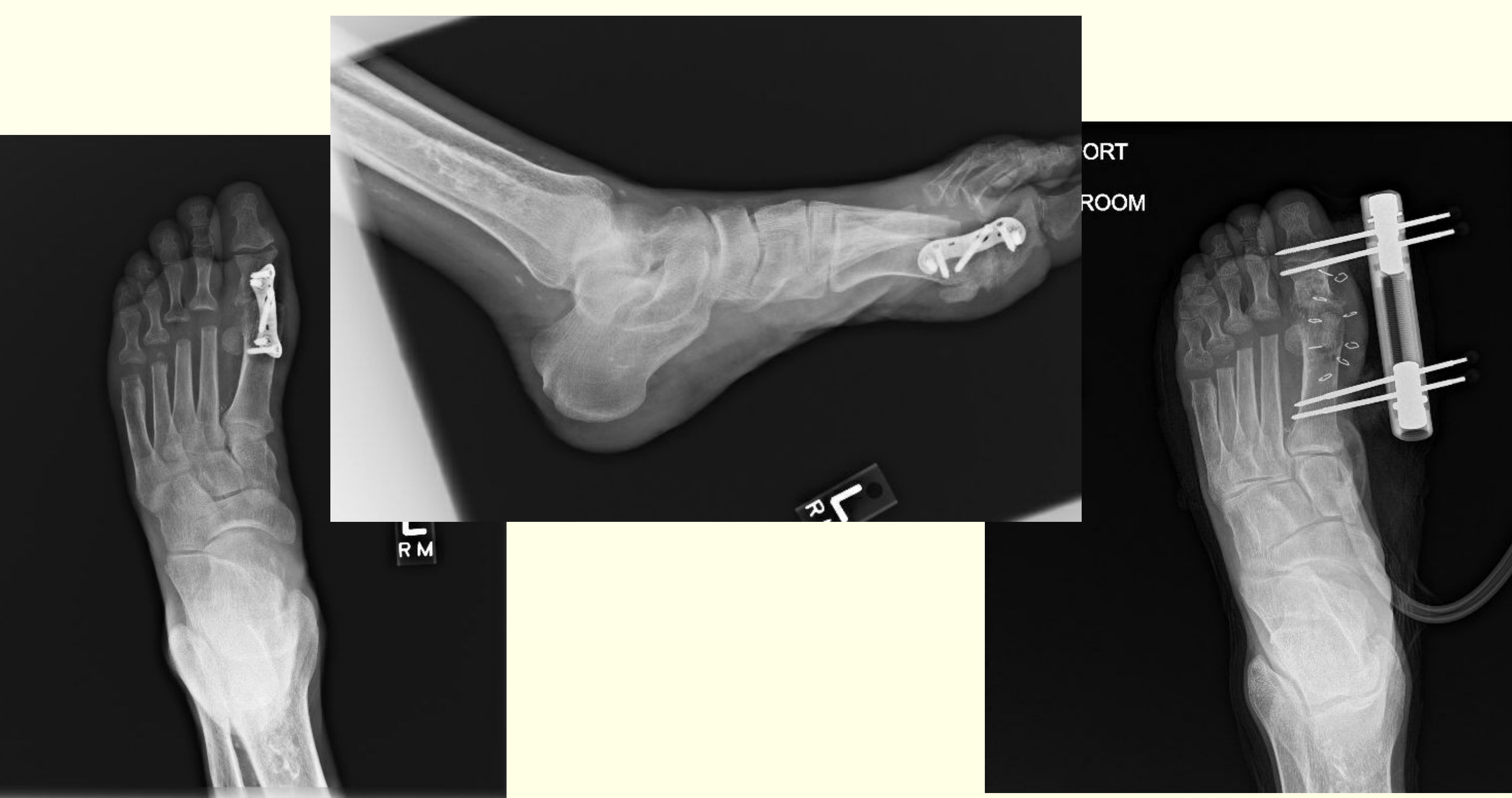
The purpose of this case study was show a different way to manage complications after a first metatarsal phalangeal joint arthrodesis, with associated osteomyelitis.

Level of Evidence: V

LITERATURE REVIEW

The first Metatarsal phalangeal joint arthrodesis is a common procedure most physicians turn to after exhausting conservative measures for hallux valgus, hallux rigidus, and osteoarthritis^{1, 2, 4}. “The reported frequency of unions from multiple cases studies range from 88%-100%”^{2,5}, however there can always be complications in any case. Some of those complications include non-unions, infected hardware, and wound dehiscence³. Korim et al reported an infection rate of 2% after a first metatarsal phalangeal fusion¹. However, the literature does not provide information on how to deal with these infections, once they occur. After a thorough literature review, there are no published papers that discuss the surgical dehiscence rates and how to manage your patients wounds after a first metatarsal phalangeal arthrodesis. The purpose of this study is to show insight on how to correct a surgical dehiscence wound with a new novelty technique of fish skin graft.

Figures: Left: Preoperative AP Xray of 1st MPJ fusion, Middle: Lateral Preoperative view of 1st MPJ fusion, Right: Post operative AP Xray with mini external fixator application



Figures: A: Surgical dehiscence with exposure of plate B: Surgical debridement before application of fish skin graft C: External fixator with application fish skin graft D: Healed 1st Metatarsal phalangeal wound

CASE STUDY

We present a case of a 61 y/o African American male with a past medical history of peripheral neuropathy, hypertension, human immunodeficiency virus on HAART, hepatitis C virus, Chronic hepatitis B virus, and chronic wounds to left foot presented to the emergency department three weeks status post first metatarsal phalangeal joint arthrodesis and panmetatarsal head resection of the left foot. Patient’s chief complaint was left foot pain with associated fevers at home. On admission his labs exhibited: WBC 7.7, neutrophils 80.3, CRP 19.5, ESR 121, A1c 7.3%.

Our examination of the patient revealed he recently had his stitches removed, but patient failed to check his feet since the event. A full thickness wound with exposed hardware was present to the dorsal aspect of the left first metatarsal phalangeal joint measuring 3.5 x 1.1 x 0.3cm. The wound base was fibrotic and necrotic, but no fluctuance, crepitus, or tracking was found. Probe to bone test was positive. Radiographs disclosed periosteal reactions noted around the first metatarsal head, however osteomyelitis could not be ruled out. Patient was ultimately admitted and placed on broad spectrum intravenous antibiotics (IV). The patient elected to undergo an incision and drainage of the left first metatarsal with bone biopsy, application of mini external fixator, removal of infected hardware, and fish skin graft application. Post surgery, six weeks of long term antibiotics were suggested due to positive wound cultures showing pseudomonas aeruginosa and a bone biopsy exhibiting acute osteomyelitis. The external fixator was removed two weeks post op and a second graft was applied with a total contact cast. After careful postoperative treatment of IV antibiotics, by-weekly debridements, negative pressure therapy, and offloading the surgical site the wound size decreased to 2.7 x 0.6 x 0.2cm in seven weeks. In a matter of few months, this patient had completely healed and avoided amputation.

ANALYSIS/ DISCUSSION

Surgical dehiscence wounds can be complicated due to multiple factors including infections, painful hardware, or even immunocompromised patients. From this case study we can appreciate a different technique to aid in the correction of a failed and complicated first metatarsal phalangeal joint arthrodesis. With a multimodal approach using antibiotics, off-loading, and two applications of this fish skin, omega 3 graft we were able to successfully heal the surgical dehiscence site. The fish skin graft rapidly incorporated into the wound bed within a few days and filled the large surgical defect with exposed bone and hardware⁶. Multimodal treatment options should be utilized to manage complications after lower extremity surgery and Omega 3 fish skin grafts should be considered to help heal these complicated wounds.

REFERENCES

- Harris, E., Moroney, P., & Tourné, Y. (2017). Arthrodesis of the first metatarsophalangeal joint—A biomechanical comparison of four fixation techniques. *Foot and Ankle Surgery*, 23(4), 268–274. doi: 10.1016/j.fas.2016.07.005
- Korim, M. T., Mahadevan, D., Ghosh, A., & Mangwani, J. (2017). Effect of joint pathology, surface preparation and fixation methods on union frequency after first metatarsophalangeal joint arthrodesis: A systematic review of the English literature. *Foot and Ankle Surgery*, 23(3), 189–194. doi: 10.1016/j.fas.2016.05.317
- Anderson JJ, Hansen M, Rowe GP, Swayzee Z. Complication rates in diabetics with first metatarsophalangeal joint arthrodesis. *Diabet Foot Ankle*. 2014;5:10.3402/dfa.v5.24649. Published 2014 Jun 27. doi:10.3402/dfa.v5.24649
- Roukis T,S. First Metatarsal-Phalangeal Joint Arthrodesis: Primary, Revision, and Salvage of Complications. *Clinics in Podiatric Medicine and Surgery*. July 2017
- Roukis T,S. Salvage arthrodesis for failed first metatarsophalangeal joint arthroplasty: A network meta-analysis. *Foot and Ankle Surgery*. August 2019.
- Trinh TT, Dünschede F, Vahl CF, Dorweiler B. Marine Omega3 wound matrix for the treatment of complicated wounds. *Phlebologie*. 2016;45(2):93-98.

FINANCIAL DISCLOSURE

Dr. Hook is a consultant speaker for Fish skin Omega 3 grafts. No other financial disclosures.