Incidence of Gossypiboma: A Call for Diligence in the Peripheral Wound Care Setting

Brittany E. Mayer, DPM, and **Noman A. Siddiqui, DPM**

Research conducted at the Rubin Institute for Advanced Orthopedics, Sinai Hospital of Baltimore, Baltimore, MD.

Financial Disclosures: BEM has nothing to disclose. NAS receives research support from Celgene and is a consultant for Orthofix, Arthrex, and Stryker Trauma.

Purpose

Foot and ankle surgeons often rely on visiting home health personnel, wound care facilities, and peripheral staffing to manage wound care and dressing regimens in the outpatient setting. While the utilization of these peripheral centers and providers facilitate wound care for patients, retained dressings (i.e., gossypiboma) resulting in iatrogenic lower extremity infections do occur, although they are rare. This case discusses the importance of diligent wound care in the setting of an iatrogenic lower extremity infection caused by peripheral care providers.

Literature Review

As of 2002, home health care had become the fastest growing segment of the health care delivery system. Patients are being discharged from the hospital earlier, creating a need for specialized and sophisticated nursing procedures to be performed in the home/outpatient setting.[1] However, the increase in home nursing and outpatient services has a direct correlation with increased infections acquired while the patient was receiving a service from a home health agency.[2]

With the increased demand on outpatient wound care and nursing services, there is a direct correlation with undocumented wound complications witnessed by supervising physicians and practitioners. Complications can occur when the initial wound care plan is not adhered to or when non-prescribed care is incorporated into the wound care plan. In extreme cases, wound care materials have accidentally been left behind in patients. This is known as gossypiboma, which is a mass of cotton material (e.g., gauze, sponges, towels) inadvertently left in the body cavity.

Literature discussing wound-care-induced complications and the incidence of gossypiboma in the lower extremity are scant. In 2014, Arora and Johal[3] published a case report of retained packing in the lower extremity following femoral plating. The postoperative course was complicated with a nonunion requiring reoperation. Upon revision, a gossypiboma (retained surgical sponge) was discovered at the operative site, which was noted to be the causative factor of the nonunion.

Case Study

Our case study involves a 51-year-old woman with diabetes, midfoot Charcot deformity, and concomitant chronic plantar wound. The patient had received wound care from multiple providers since the onset of her wound in 2011 through her final surgical procedure in May 2018.

Surgical/Wound Care Timeline

September 2011:
- Initial patient consultation of left midfoot deformity with plantar wound
- Treated with iodoform packing by local wound care facility prior to surgical consultation

October 2011:
- LisFranc and midtarsal joint arthrodesis for deformity correction with external fixation frame
- Continuation of wound care at skilled nursing facility and wound care centers

March 2015:
- Last documented order/prescription for usage of iodoform packing, performed at wound care facility

October 2016:
- Plantar midfoot exostectomy, wound débridement, and closure via soft-tissue re-arrangement/advancement

December 2017:
- Deformity correction via midfoot osteotomy
- Ankle arthrodesis via external fixation frame

March 2018:
- Removal of external fixation
- Insertion of antibiotic-coated hindfoot fusion nail

May 2018 Hospitalization:
- Patient returns to Emergency Department and admitted due to malaise, fever, and drainage from recurrent left plantar heel wound
- Plantar wound tracking approximately 3.6 cm
- Evidence of infected nonunion at the level of the ankle joint (Figures 1–4)

May 2018 Surgery:
- Removal of infected intramedullary (IM) hindfoot fusion nail, with discovery of retained iodoform packing on proximal end of hindfoot nail upon removal
- Insertion of antibiotic spacer (Figure 5)

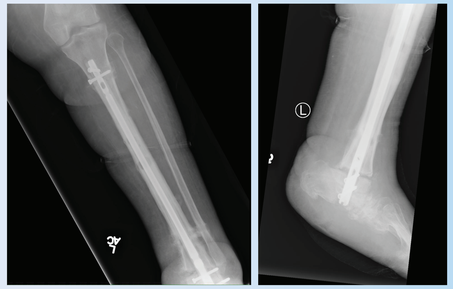

Figures 1 and 2. AP and lateral view radiographs of infected intramedullary (IM) nail with infected nonunion of the ankle joint.

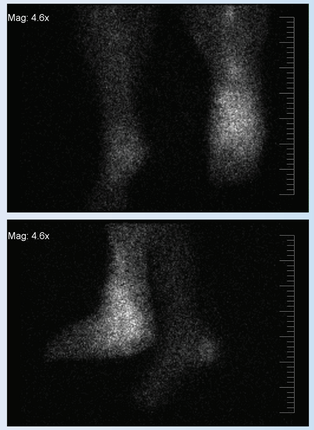

Figures 3 and 4. Nuclear medicine bone scan in AP and lateral orientation obtained prior to IM nail removal.

Figure 5. Retained packing was observed at the proximal portion of the antibiotic-coated IM nail. Upon removal, packing was adhered to the nail.

Results

The surgical team correlated the complication/nonunion with the intraoperative discovery of gossypiboma (iodoform packing) upon removal of previously implanted antibiotic-coated IM hindfoot fusion nail. After nail and gossypiboma removal, the canal was copiously irrigated with saline, followed by impregnation of the tibial canal with antibiotic cement. At 16 months follow-up, the patient is doing well and ambulating in a protected boot. A successful tibial-talar-calcaneal arthrodesis was achieved via antibiotic cement without any retained internal hardware (Figures 6–9).

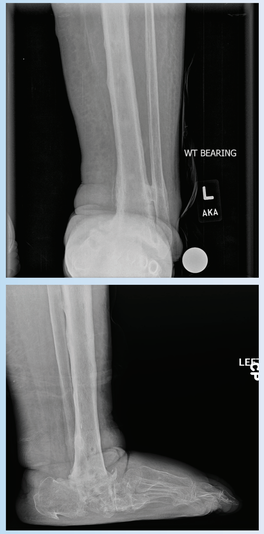

Figures 6 and 7. Postoperative AP and lateral view radiographs obtained at 16-month follow-up show that hindfoot fusion was achieved.

Figures 8 and 9. Clinical photographs of patient's left lower extremity at most recent follow-up visit.

Analysis & Discussion

This case study provides evidence that while rare, incidence of gossypiboma in the lower extremities can occur. While surgical revision was favorable for this patient, avoiding preventable iatrogenic complications, such as a gossypiboma, is imperative. As foot and ankle surgeons, this study directs attention to the need for meticulous communication between the primary provider and peripheral wound care team to ensure safe wound care practices for our patients.

References

1. Zwanziger PJ, Roper S. Bacterial counts and types found on wound care supplies used in the home setting. J Wound Ostomy Continence Nurs. 2002;29(2):83–7.
2. Rosenheimer L. Establishing a surveillance system for infections acquired in home healthcare. Home Healthc Nurse. 1995;13(3):20–6.
3. Arora RK, Johal KS. Gossypiboma in Thigh: A Case Report. J Orthop Case Rep. 2014;4(3):22–4.